


**PATIENT PRESENTING CLINICAL SIGNS**

Kenai Roper Presented 3/1 with nasal discharge from right nostril and conjunctivitis of right eye that had been present for 1 week. No response to Augmentin and Neopolydex. Recheck on 3/18 showed little improvement. NSF on radiographs. Tear test was 5 on right eye. Severe rhinitis w/ opaque plaque over ventral conchae on nasal exam. Upon exam today, no symptoms present. No nasal discharge and right eye appears normal. Biochemistry was within normal limits.

**SPECIES**

Canine

**COMPUTED TOMOGRAPHIC STUDY OF THE NASAL CAVITIES**
**BREED**

Plain study available for review.

**Mixed**
**COMPUTED TOMOGRAPHIC FINDINGS**

Thin and smoothly folded conchae and turbinates with even smooth mucosal lining. The osseous lining of the nasal cavities is intact.

**SEX**

Neutered Male

**COMPUTED TOMOGRAPHIC DIAGNOSIS**

- Structurally normal CT study of the nasal cavities and paranasal sinuses

**AGE**

5 Years 10 Months

**INTERPRETATION OF FINDINGS & FURTHER RECOMMENDATIONS**

The CT study reveals no structural abnormality of the nasal cavities and frontal sinuses. Acute inflammation or infection cannot be ruled out entirely. However, there is no structural evidence of rhinosinusitis, foreign material, a nasal mass, or fungal rhinitis.

**INTERPRETED BY**

Nele Eley (Ondreka),  
 DVM Dr. med. vet.,  
 DipECVDI

**HOSPITAL NAME**

State Ave Vet

**REFERRING VET**

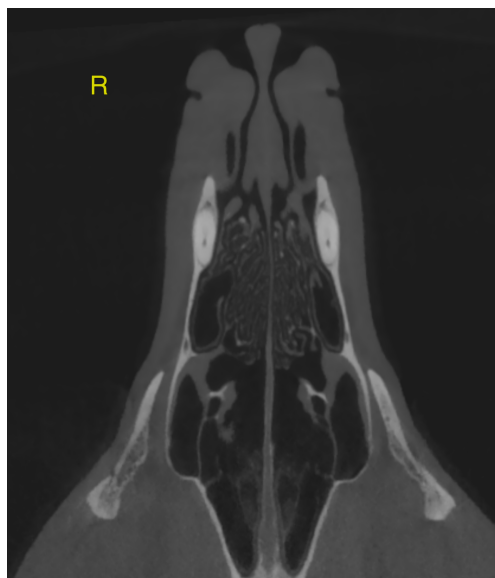
Dr. Raul Casas-Dolz

**INVOICE**

36533

**DATE**

3/29/22





**PATIENT**

Kenai Roper

The information and recommendations provided are based on the images presented by the referring veterinarian. No evaluation can be communicated regarding pathology that was not visible in the image/video clips provided.

**SPECIES**

Canine

Thank you for this referral. If the clinical or image interpretation does not parallel your findings or if I can be of any further assistance please contact me.

**BREED**

Mixed

**Nele Eley (Ondreka)**, DVM, Dr. med. vet., DipECVDI  
European Specialist in Veterinary Diagnostic Imaging, Cert. Radiology,  
Senior lecturer University of Giessen/Germany, Veterinary Faculty, Department of Radiology.  
Nele.Eley@sonopath.com

**SEX**

Neutered Male

**AGE**

5 Years 10 Months

**INTERPRETED BY**

Nele Eley (Ondreka),  
DVM Dr. med. vet.,  
DipECVDI

**HOSPITAL NAME**

State Ave Vet

**REFERRING VET**

Dr. Raul Casas-Dolz

**INVOICE**

36533

**DATE**

3/29/22