



PATIENT

Finn Cookerly

PRESENTING CLINICAL SIGNS

chronic gag/cough. not clear if it is truly lung related or GI related. Trying to differentiate
 Abnormal PE/Chem/CBC/UA Results: CBC normal, Chemistry normal except ALT = 679, AST = 70

SPECIES

Canine

RADIOGRAPHIC STUDY OF THE THORAX

Right/left lateral and ventrodorsal views totaling 3 images available for review.

BREED

Boston

RADIOGRAPHIC FINDINGS

Widening of the caudodorsal mediastinum is seen and cranial position of the gastric fundus and lower esophageal sphincter are seen.

SEX

Neutered Male

The lung presents a mild bronchointerstitial pattern.

The cardiac silhouette is upright and thin.

Mild generalized tracheal hypoplasia is noted.

AGE

3

A sharply delineated mineral opacity of 2.5 cm length and 4mm width is seen in the cranial abdomen on the left lateral view.

Gastrointestinal aerophagia is noted.

INTERPRETED BY

Nele Eley, DVM
 Dr. med. Vet. DipECVDI

RADIOGRAPHIC DIAGNOSIS

- Suspect hiatal hernia.
- Bronchointerstitial lung pattern.
- Suspect gastric foreign material.

HOSPITAL NAME

Q Street Animal Hospital

INTERPRETATION OF THE FINDINGS & FURTHER RECOMMENDATIONS

The radiographic findings are suggestive for hiatal hernia. Paraesophageal hernia, gastroesophageal invagination, esophageal foreign material, diverticulum, or mass are thought unlikely as differential diagnoses.

REFERRING VET

Bretschneider

The bronchointerstitial lung pattern may indicate prior aspiration pneumonia, however, active bronchitis such as eosinophilic bronchopneumopathy or infectious bronchitis cannot be ruled out entirely as a differential diagnosis even though considered by far less likely.

INVOICE

51238

DATE

3-29-22



PATIENT

Finn Cookerly

SPECIES

Canine

BREED

Boston

SEX

Neutered Male

AGE

3

INTERPRETED BY

Nele Eley, DVM
Dr. med. Vet. DipECVDI

HOSPITAL NAME

Q Street Animal
Hospital

REFERRING VET

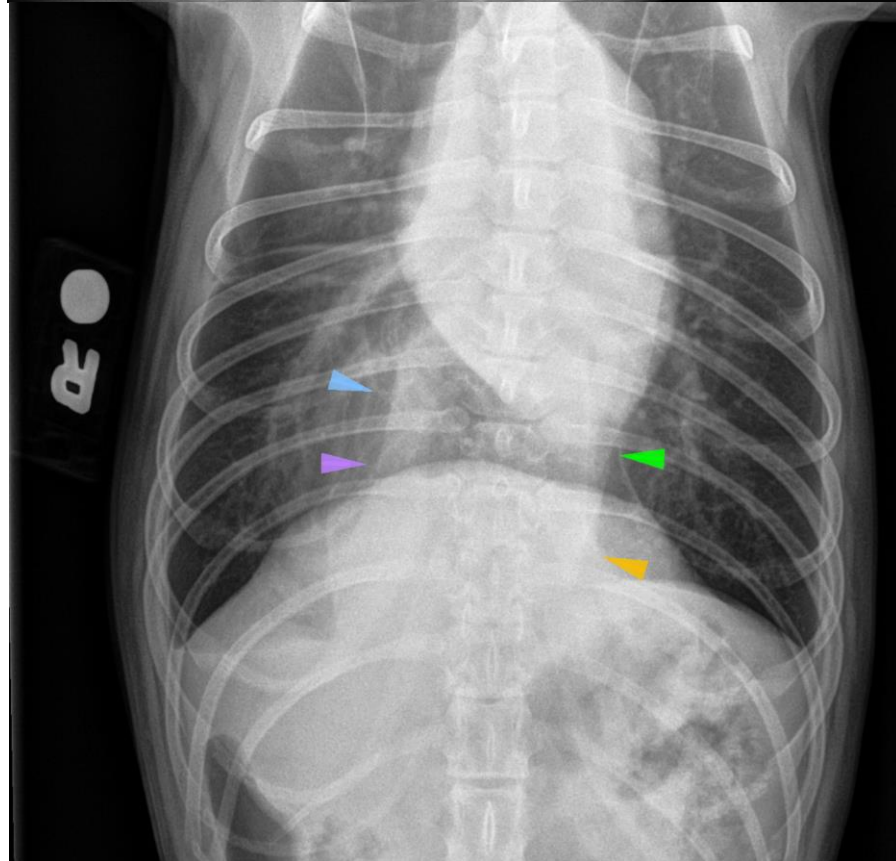
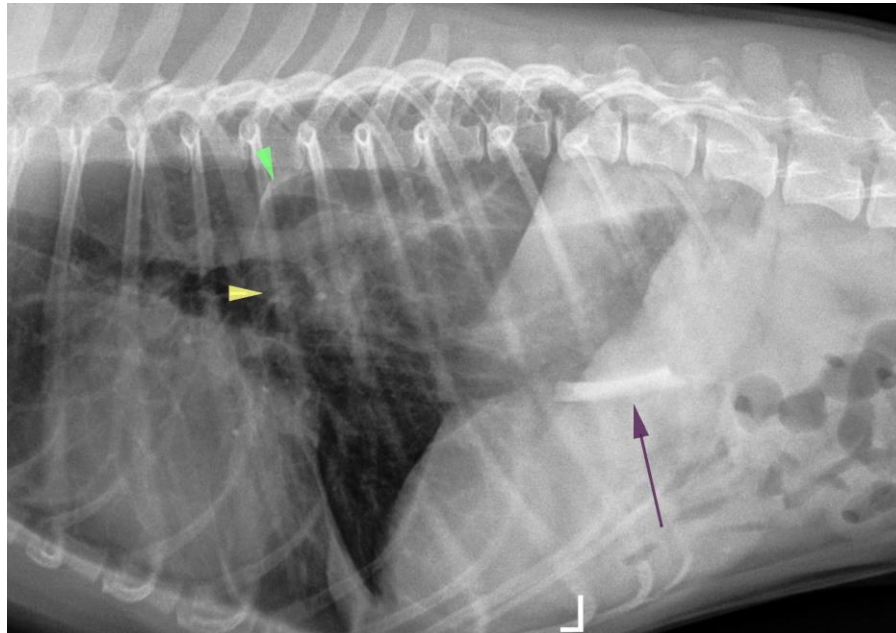
Bretschneider

INVOICE

51238

DATE

3-29-22





PATIENT

Finn Cookerly

The information and recommendations provided are based on the images presented by the referring veterinarian/sonographer. No evaluation can be communicated regarding pathology that was not visible in the image/video clips provided.

Thank you for this referral. If the clinical or image interpretation does not parallel your findings or if I can be of any further assistance please contact me.

SPECIES

Canine

Nele Eley, DVM, Dr. med. vet., DipECVDI
European Specialist in Veterinary Diagnostic Imaging, Cert. Radiology,
Senior lecturer University of Giessen, Germany, Veterinary Faculty, Department of Radiology
Nele.Eley@sonopath.com

BREED

Boston

SEX

Neutered Male

AGE

3

INTERPRETED BY

Nele Eley, DVM
Dr. med. Vet. DipECVDI

HOSPITAL NAME

Q Street Animal
Hospital

REFERRING VET

Bretschneider

INVOICE

51238

DATE

3-29-22