



PATIENT

Elyse Rebel Dog
Rescue

PRESENTING CLINICAL SIGNS

Rescued dog from Texas ..not sure about age . was heartworm positive and treated Has 2 episodes of seizures (Feb 27, March 26)
Abnormal PE/Chem/CBC/UA Results: Worn teeth and covered with tartar otherwise normal unremarkable blood work

SPECIES

Canine

RADIOGRAPHIC STUDY OF THE THORAX & ABDOMEN

Right/left lateral and ventrodorsal views of the thorax and abdomen totaling 7 images available for review.

BREED

Boxer Mix

RADIOGRAPHIC FINDINGS

Abdomen

Moderate right sided coxofemoral joint osteoarthritis secondary to hip dysplasia is seen. The left coxofemoral joint presents within age related normal limits.

SEX

Female Spayed

Moderate ventrally bridging spondyloses are noted between L6 and L7 as well as at the lumbosacral junction.

AGE

6 Years

The 12th right rib presents focal widening with smoothly delineated margins and no signs of aggressive osteolysis at the transition between the proximal and mid third of the rib.

INTERPRETED BY

Nele Eley, DVM
Dr. med. Vet. DipECVDI

The stomach is post-prandial.

The radiographic presentation of the kidneys and urinary bladder is considered within normal limits.

The small intestinal loops are evenly distributed throughout the mid abdomen without signs of dilation.

HOSPITAL NAME

St. Catherine's Animal
Hospital

Thorax

Moderate caudal thoracic spondyloses are seen.

The radiographic presentation of the cardiac silhouette is within normal limits. The vertebral heart score is 10.5 which is within the reference range for a boxer.

REFERRING VET

Dr. Mena

There is a caudodorsally accentuated bronchial lung pattern with mild peribronchial cuffing.

Course and width of the trachea are considered within normal limits.

INVOICE

51237

There is no evidence of abnormal mediastinal widening.

RADIOGRAPHIC DIAGNOSIS

DATE

3-29-22

- Osteoproliferative lesion of the right 12th rib without signs of aggressive biological behavior.
- Right coxofemoral joint osteoarthritis secondary to hip dysplasia.
- Spondyloses.



PATIENT

Elyse Rebel Dog
Rescue

- Bronchial lung pattern with caudodorsal accentuation.
- Normal radiographic presentation of the cardiac silhouette.
- Normal radiographic presentation of the abdominal organs.

INTERPRETATION OF THE FINDINGS & FURTHER RECOMMENDATIONS

SPECIES

Canine

A caudodorsally accentuated bronchial lung pattern with mild peribronchial cuffing is noted which indicated potential for active lower airway disease. Infectious bronchitis such as parasitic, bacterial, viral, or mixed is one potential differential diagnosis. Allergic / eosinophilic bronchopneumopathy cannot be ruled out either. In case of pertinent clinical signs, testing for heartworm according to the guidelines of the American Heartworm Society as well as airway endoscopy with airway sampling could be considered. www.heartwormsociety.org

BREED

Boxer Mix

The osteoproliferative lesion of the right 12th rib reveals no overt signs of aggressive biological behavior. Healing rib fracture is a primary differential diagnosis, however, osteosarcoma, chondrosarcoma, and other neoplasia such as osteochondroma cannot be ruled out entirely and radiographic recheck in 4 weeks is recommended.

SEX

Female Spayed

AGE

6 Years

INTERPRETED BY

Nele Eley, DVM
Dr. med. Vet. DipECVDI

HOSPITAL NAME

St. Catherine's Animal
Hospital

REFERRING VET

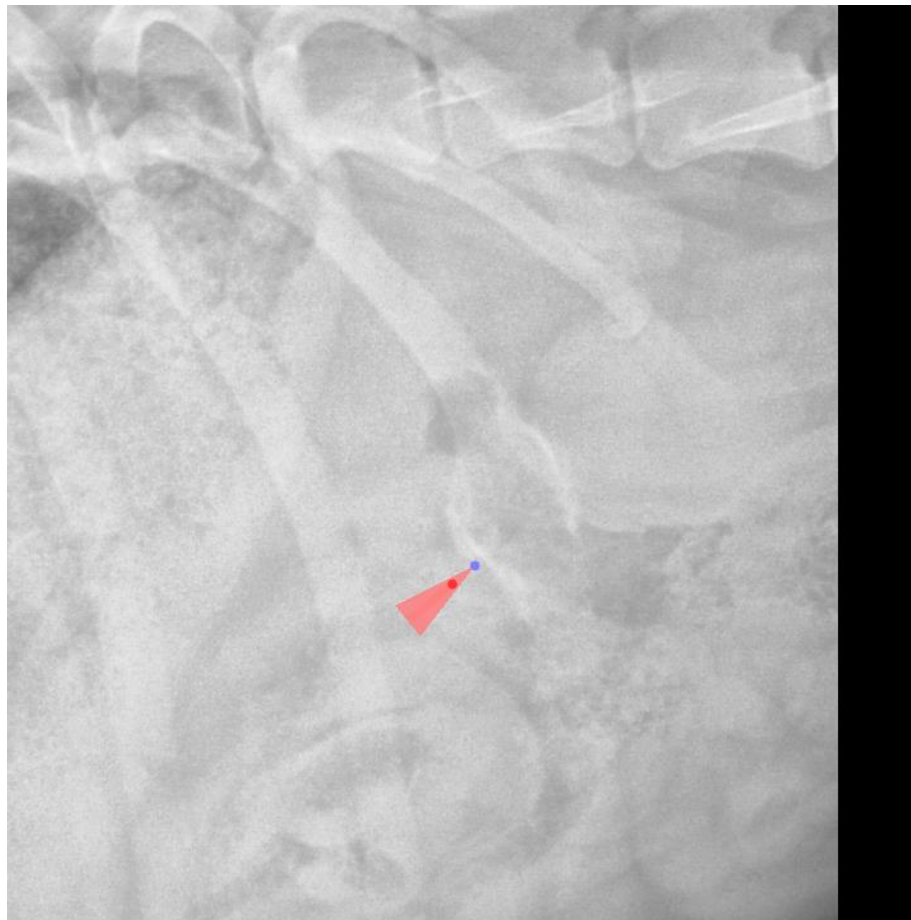
Dr. Mena

INVOICE

51237

DATE

3-29-22





PATIENT

Elyse Rebel Dog
Rescue

SPECIES

Canine

BREED

Boxer Mix

SEX

Female Spayed

AGE

6 Years

INTERPRETED BY

Nele Eley, DVM
Dr. med. Vet. DipECVDI

HOSPITAL NAME

St. Catherine's Animal
Hospital

REFERRING VET

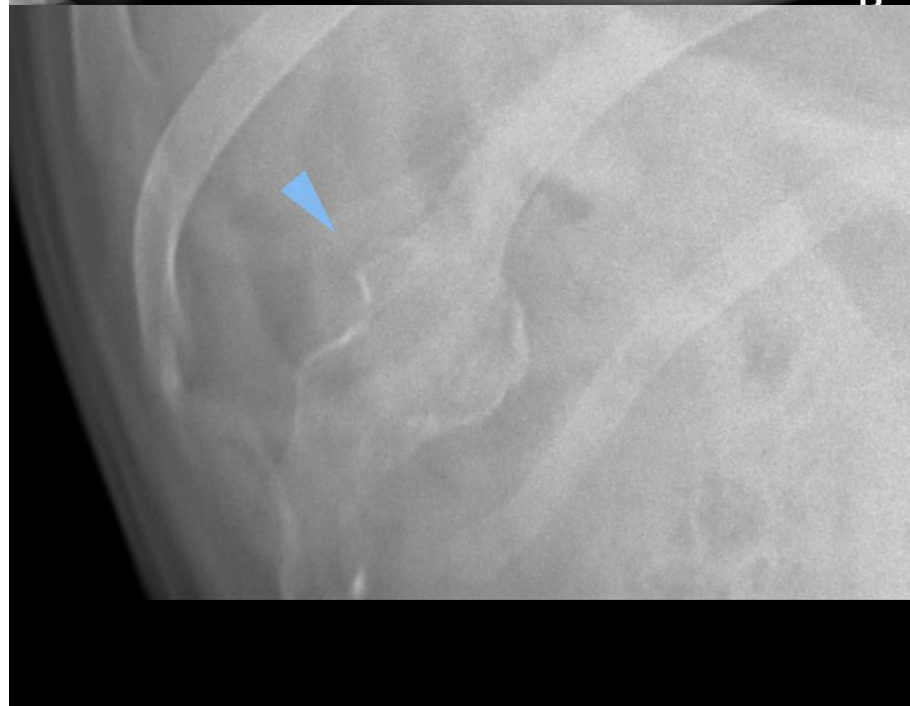
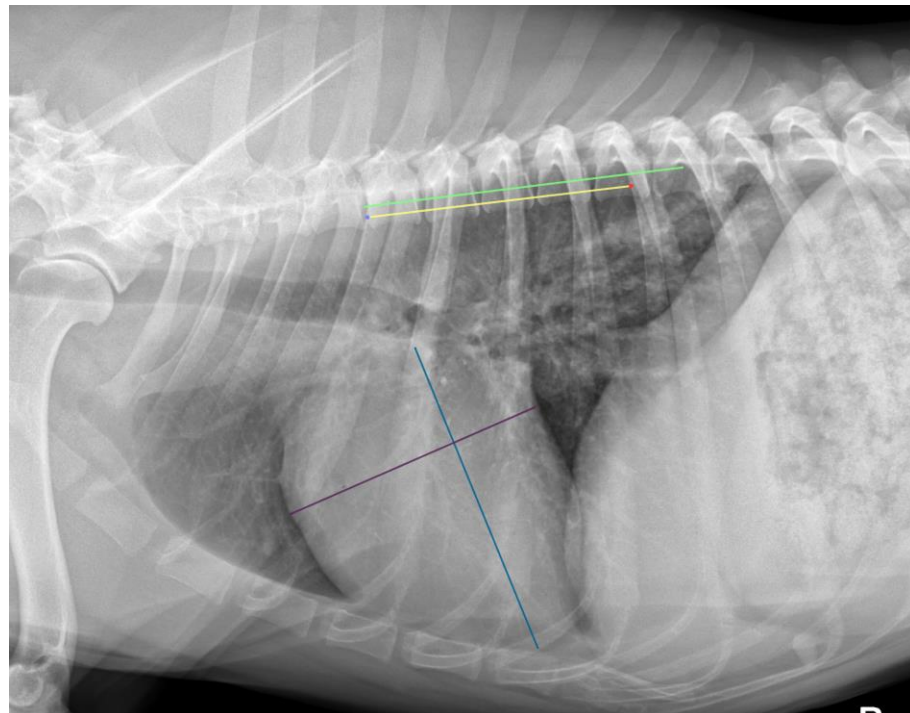
Dr. Mena

INVOICE

51237

DATE

3-29-22





PATIENT

Elyse Rebeld Dog
Rescue

The information and recommendations provided are based on the images presented by the referring veterinarian/sonographer. No evaluation can be communicated regarding pathology that was not visible in the image/video clips provided.

Thank you for this referral. If the clinical or image interpretation does not parallel your findings or if I can be of any further assistance please contact me.

SPECIES

Canine

Nele Eley, DVM, Dr. med. vet., DipECVDI
European Specialist in Veterinary Diagnostic Imaging, Cert. Radiology,
Senior lecturer University of Giessen, Germany, Veterinary Faculty, Department of Radiology
Nele.Eley@sonopath.com

BREED

Boxer Mix

SEX

Female Spayed

AGE

6 Years

INTERPRETED BY

Nele Eley, DVM
Dr. med. Vet. DipECVDI

HOSPITAL NAME

St. Catherine's Animal
Hospital

REFERRING VET

Dr. Mena

INVOICE

51237

DATE

3-29-22