



PATIENT PRESENTING CLINICAL SIGNS

Oliver Tive increased respiratory rate and effort for the past month but has dramatically worsened in the past 2 days, presented in respiratory distress.

SPECIES Abnormal PE/Chem/CBC/UA Results: Increased effort and resp rate (60) . temp 101. pleural effusion apparent. removed 80 ml of slightly cloudy fluid from left hemithorax then repeated radiographs. cytology is a lymphocyte rich effusion which could be due to heart disease, neoplasia, or chylous effusion.

Feline

BREED Right/left lateral and ventrodorsal views of the thorax totaling 3 images available for review.

Feline

SEX Multiple spondyloses are seen within the thoracolumbar spine.

Neutered Male The ribcage is expanded. The lungs are deeply inflated. The lobar margins are, however, retracted from the thoracic wall and rounded. Pleural fissure lines and increased pleural soft tissue opacity are seen.

AGE The cardiac silhouette is enlarged. Approximate vertebral heart score is 9.5, upper reference 8.5 in cats. Atrial enlargement is seen on the orthogonal view. Basico-apical enlargement of the cardiac silhouette is indicated by elevation of the trachea on the lateral view.

14

INTERPRETED BY The lung presents a mild vascular pattern. No evidence of pulmonary nodules or masses is seen.

Nele Eley, DVM
Dr. med. Vet. DipECVDI There is no direct evidence of a mediastinal mass.

RADIOGRAPHIC DIAGNOSIS

- HOSPITAL NAME**
- Moderate bilaterally symmetric pleural effusion with partial collapse of the lung.
 - Cardiomegaly with atrial enlargement
 - Mild vascular lung pattern.
 - Multiple spondyloses.
- Northshore
Veterinary Hospital

INTERPRETATION OF THE FINDINGS & FURTHER RECOMMENDATIONS

REFERRING VET The radiographic findings strongly indicate presence of cardiac pathology such as cardiomyopathy with atrial enlargement and congestive cardiac failure as underlying cause of the pleural effusion. Further definition by means of a cardiac echo is recommended if not performed already.

Kimberly Barron

INVOICE

57510

DATE

3-28-23



PATIENT

Oliver Tive

SPECIES

Feline

BREED

Feline

SEX

Neutered Male

AGE

14

INTERPRETED BY

Nele Eley, DVM
Dr. med. Vet. DipECVDI

HOSPITAL NAME

Northshore
Veterinary Hospital

REFERRING VET

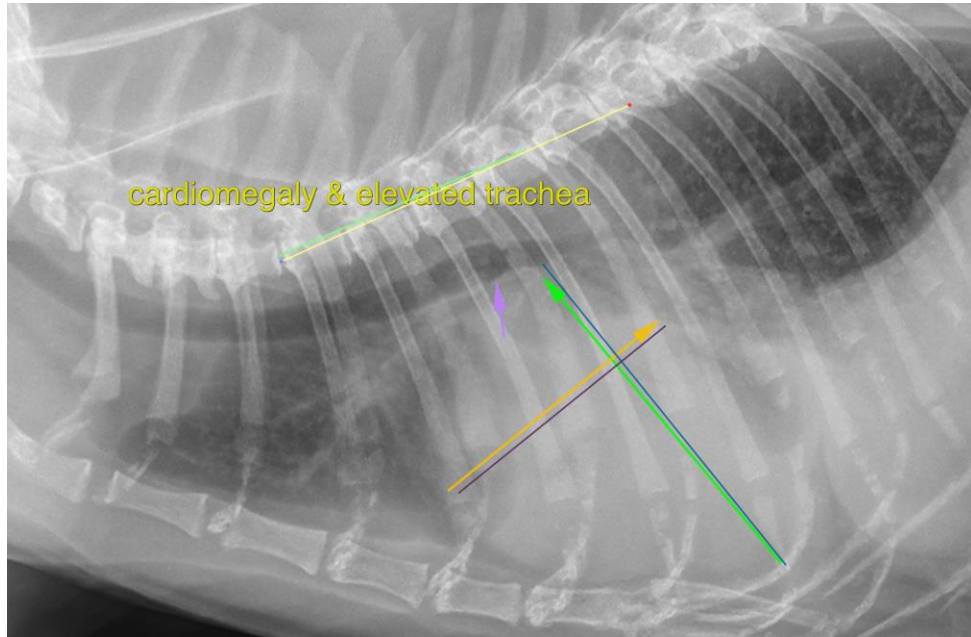
Kimberly Barron

INVOICE

57510

DATE

3-28-23



The information and recommendations provided are based on the images presented by the referring veterinarian/sonographer. No evaluation can be communicated regarding pathology that was not visible in the image/video clips provided.

Thank you for this referral. If the clinical or image interpretation does not parallel your findings or if I can be of any further assistance please contact me.

Nele Eley, DVM, Dr. med. vet., DipECVDI
European Specialist in Veterinary Diagnostic Imaging, Cert. Radiology,
Senior lecturer University of Giessen, Germany, Veterinary Faculty, Department of Radiology
Nele.Eley@sonopath.com