

**PATIENT PRESENTING CLINICAL SIGNS**

Roxy Brash Pet presented for Skull CT Scan. Clinical history of yawning and then will keep mouth open for several seconds and seems in distress. Jaw will close slowly but then pet parent hears a snapping sound. Pet has yelped when jaw fully closes.

SPECIES COMPUTED TOMOGRAPHIC STUDY OF THE HEAD

Canine Plain and post contrast studies in open and closed mouth positions available for review.

BREED COMPUTED TOMOGRAPHIC FINDINGS

German Shepard Mix Both temporomandibular joints present an increase inclination angle. The mandibular condyles and maxillary fovea are flat.

SEX Subluxation and joint space divergence of the left temporomandibular joint are noted and enhanced in open mouth positions.

FS Both temporomandibular joints present subchondral bone sclerosis with new bone formation accentuating the medial margin of the joints. Mild multifocal subchondral bone erosion is noted bilaterally. The changes are moderate to severe on the left and mild to moderate on the right side.

AGE COMPUTED TOMOGRAPHIC DIAGNOSIS

4 Years, 8 Months

- Bilateral temporomandibular joint dysplasia with dynamic subluxation of the left temporomandibular joint and bilateral chronic degenerative joint disease.

INTERPRETED BY

Nele Eley (Ondreka),
DVM Dr. med. vet.,
DipECVDI

INTERPRETATION OF FINDINGS & FURTHER RECOMMENDATIONS

The CT findings suggest presence of bilateral temporomandibular joint dysplasia. Subluxation of the left temporomandibular joint is noted and enhanced in open mouth position. Both temporomandibular joints present evidence of secondary osteoarthritis which is moderate to severe on the left and mild on the right side.

HOSPITAL NAME

Mobile Pet Imaging
CFL

REFERRING VET

Borecky

INVOICE

51196

DATE

3-28-22



PATIENT

Roxy Brash

SPECIES

Canine

BREED

German Shepard Mix

SEX

FS

AGE

4 Years, 8 Months

INTERPRETED BY

Nele Eley (Ondreka),
DVM Dr. med. vet.,
DipECVDI

HOSPITAL NAME

Mobile Pet Imaging
CFL

REFERRING VET

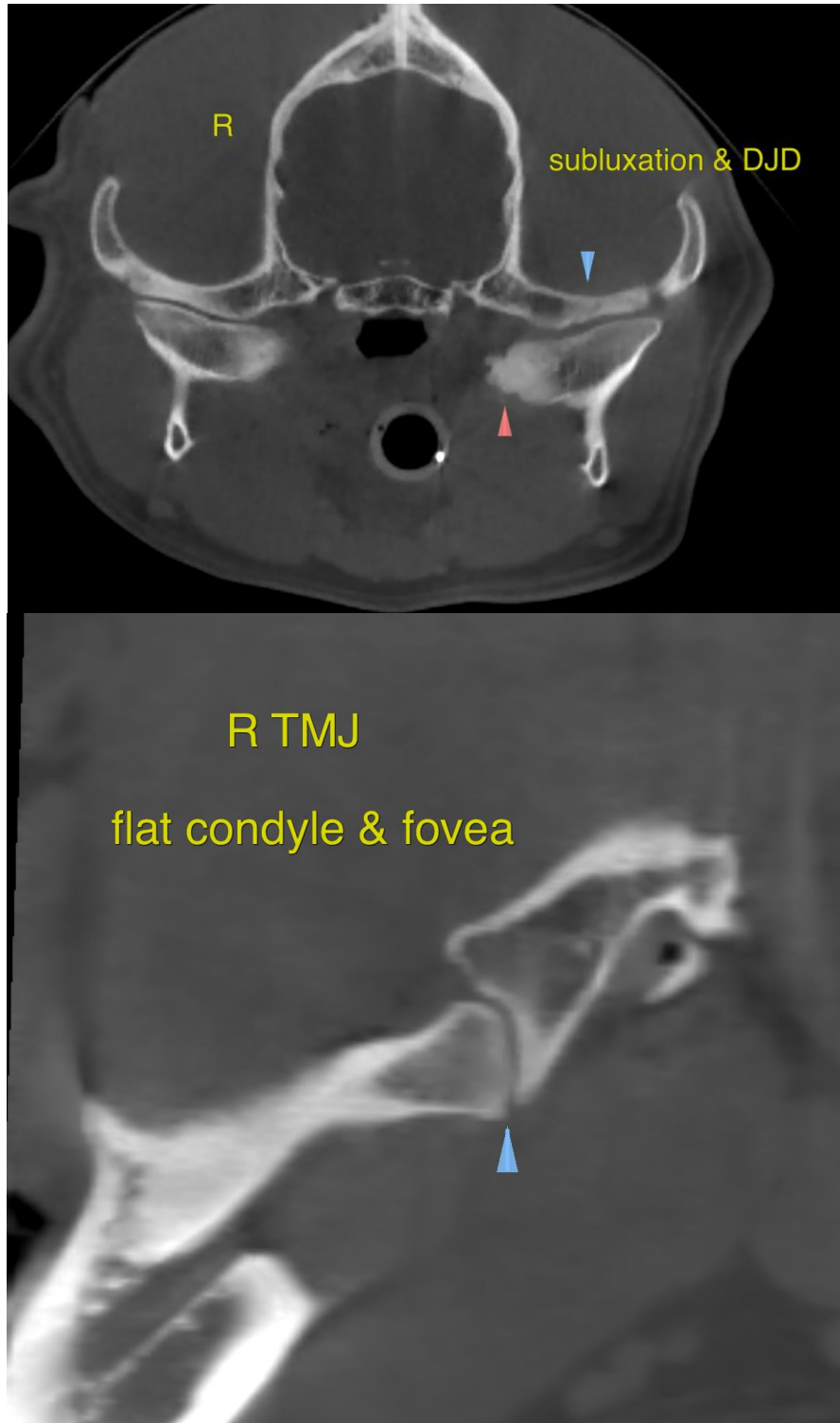
Borecky

INVOICE

51196

DATE

3-28-22





PATIENT

Roxy Brash

SPECIES

Canine

BREED

German Shepard Mix

SEX

FS

AGE

4 Years, 8 Months

INTERPRETED BY

Nele Eley (Ondreka),
DVM Dr. med. vet.,
DipECVDI

HOSPITAL NAME

Mobile Pet Imaging
CFL

REFERRING VET

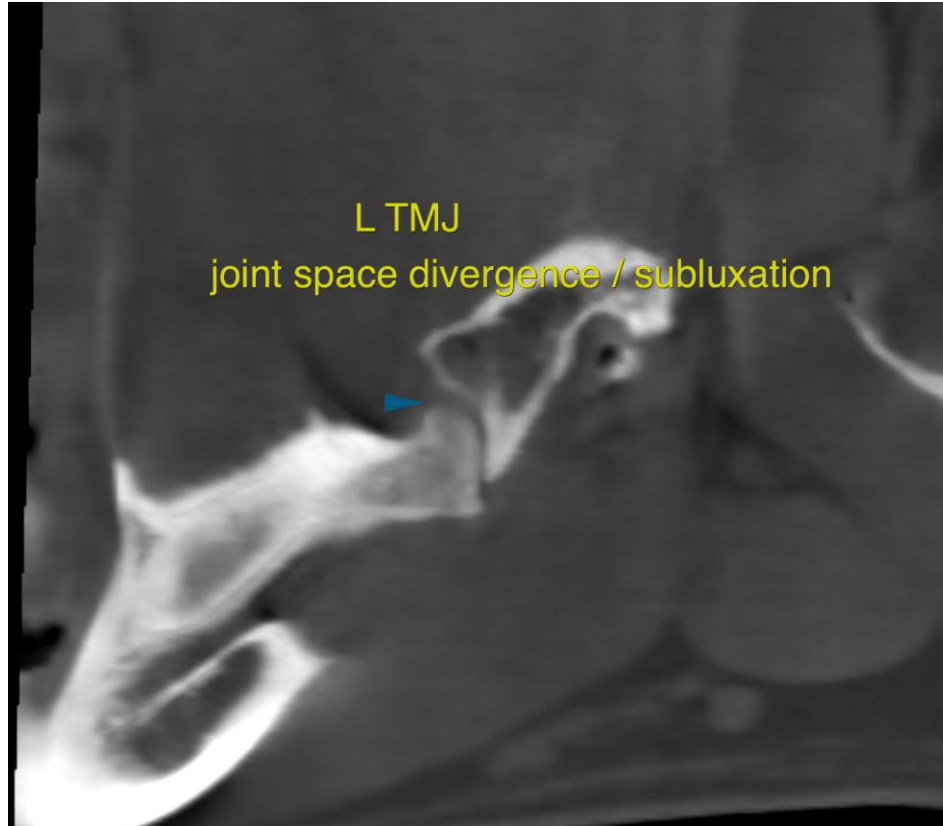
Borecky

INVOICE

51196

DATE

3-28-22



The information and recommendations provided are based on the images presented by the referring veterinarian. No evaluation can be communicated regarding pathology that was not visible in the image/video clips provided.

Thank you for this referral. If the clinical or image interpretation does not parallel your findings or if I can be of any further assistance please contact me.

Nele Eley (Ondreka), DVM, Dr. med. vet., DipECVDI
European Specialist in Veterinary Diagnostic Imaging, Cert. Radiology,
Senior lecturer University of Giessen/Germany, Veterinary Faculty, Department of Radiology.
Nele.Eley@sonopath.com