

**PATIENT**

Roscoe Animal  
Welfare League

**PRESENTING CLINICAL SIGNS**

Roscoe presents for pelvic fractures that occurred around 3/15. He is still very painful and now knuckling on both hind limbs. Physical exam MSK: pelvic fractures NEURO: knuckling on both hind feet and very painful

**SPECIES**

Canine

**COMPUTED TOMOGRAPHIC STUDY OF THE PELVIS**

Plain study available for review.

**BREED**

Pitbull Mix

**COMPUTED TOMOGRAPHIC FINDINGS**

Photon starvation artifacts superimpose with the coxofemoral joint area.

The patient has a symmetric lumbosacral transitional vertebra. The transverse processes and lateral wings of the transitional vertebra are fractured on both sides with displacement of the sacroiliac joints.

**SEX**

MN

A short oblique fracture of the body of the left sciatic bone is seen directly caudal to the left acetabulum with dorsal displacement of the fractured left sciatic bone.

**AGE**

18 Months

Bilateral cranial and caudal pubic rim fractures are seen on the pelvic floor.

**COMPUTED TOMOGRAPHIC DIAGNOSIS**

- Multiple traumatic osseous injury of the lumbosacral transitional vertebra, left sciatic bone, and pelvic floor.

**INTERPRETED BY**

Nele Eley, DVM  
Dr. med. Vet. DipECVDI

**INTERPRETATION OF THE FINDINGS & FURTHER RECOMMENDATIONS**

The fractures of the lateral wings and transverse processes of the lumbosacral transitional vertebra may render the sacroiliac junctions unstable and interfere with the anatomic pathway of the caudal lumbosacral nerve plexus. The fracture of the left sciatic bone is in the pathway of the sciatic foramen for the peripheral left sciatic nerve which contribute to the clinical signs as well. The pelvic floor fractures are less likely to be the cause of the ongoing clinical signs.

**HOSPITAL NAME**

Critical Vet  
Care/Suncoast  
Veterinary

**REFERRING VET**

Dr. Young

**INVOICE**

57458

**DATE**

3-27-23



**PATIENT**

Roscoe Animal  
Welfare League

**SPECIES**

Canine

**BREED**

Pitbull Mix

**SEX**

MN

**AGE**

18 Months

**INTERPRETED BY**

Nele Eley, DVM  
Dr. med. Vet. DipECVDI

**HOSPITAL NAME**

Critical Vet  
Care/Suncoast  
Veterinary

**REFERRING VET**

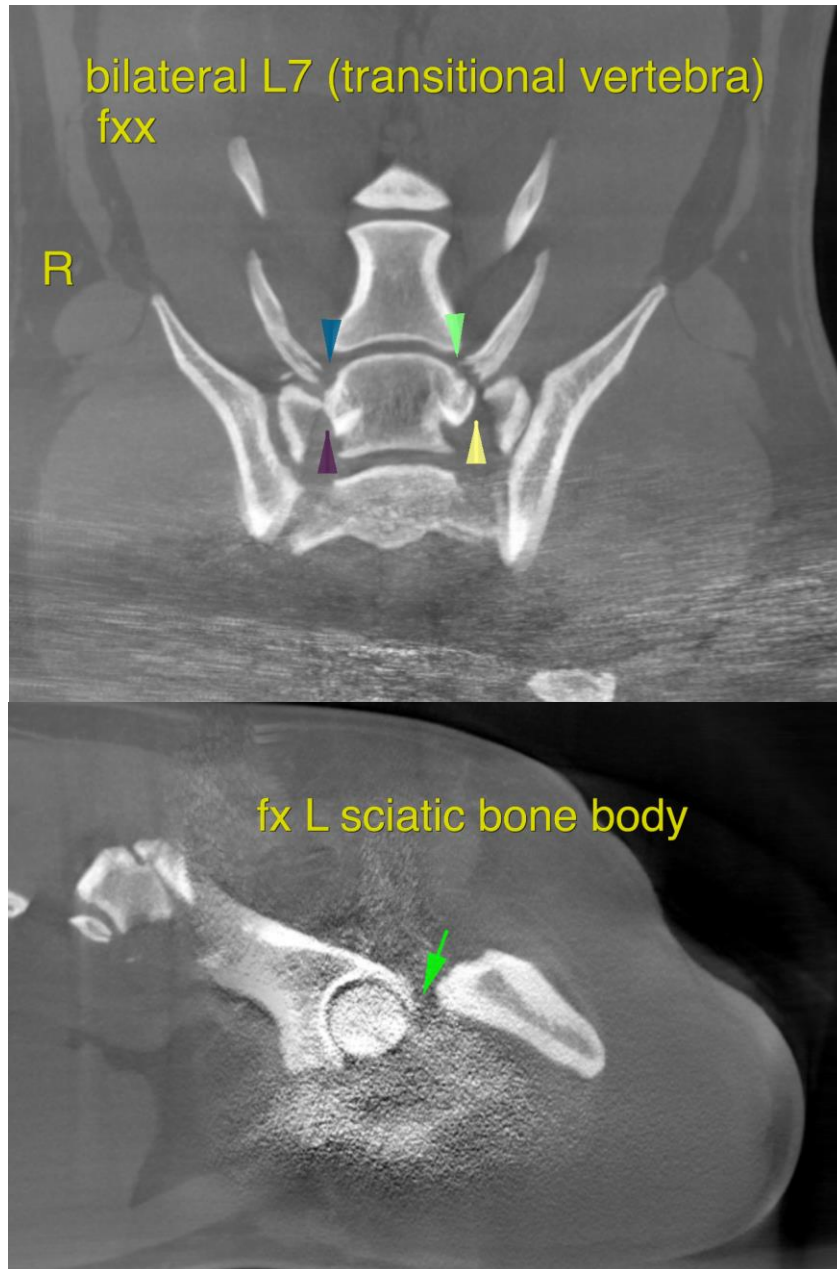
Dr. Young

**INVOICE**

57458

**DATE**

3-27-23





**PATIENT**

Roscoe Animal  
Welfare League

The information and recommendations provided are based on the images presented by the referring veterinarian/sonographer. No evaluation can be communicated regarding pathology that was not visible in the image/video clips provided.

Thank you for this referral. If the clinical or image interpretation does not parallel your findings or if I can be of any further assistance please contact me.

**SPECIES**

Canine

**Nele Eley**, DVM, Dr. med. vet., DipECVDI  
European Specialist in Veterinary Diagnostic Imaging, Cert. Radiology,  
Senior lecturer University of Giessen, Germany, Veterinary Faculty, Department of Radiology  
Nele.Eley@sonopath.com

**BREED**

Pitbull Mix

**SEX**

MN

**AGE**

18 Months

**INTERPRETED BY**

Nele Eley, DVM  
Dr. med. Vet. DipECVDI

**HOSPITAL NAME**

Critical Vet  
Care/Suncoast  
Veterinary

**REFERRING VET**

Dr. Young

**INVOICE**

57458

**DATE**

3-27-23