

**PATIENT**

Oreo Rong

**PRESENTING CLINICAL SIGNS**

O noticed blood in the stools twice last week  
Abnormal PE/Chem/CBC/UA Results: CBC, blood chem unremarkable, physical exam unremarkable

**SPECIES**

Canine

**RADIOGRAPHIC STUDY OF THE ABDOMEN**

Right/left lateral and ventrodorsal whole body views totaling 3 images available for review.

**BREED**

Shih Tzu Mix

Abdominal read requested.

**RADIOGRAPHIC FINDINGS**

The body condition score appears to be within normal limits.

**SEX**

Male Neutered

The abdominal serosal detail is maintained.

The liver, kidneys, and urinary bladder present within normal limits.

**AGE**

5 Years

A moderate amount of gas is seen within the stomach.

The small intestinal loops are turgid in appearance with gas content. No evidence of abnormal dilation of the small intestine is seen. The small intestinal loops are non-plicated. There is no evidence of radiopaque foreign material.

**INTERPRETED BY**

Nele Eley, DVM  
Dr. med. Vet. DipECVDI

A gas column can be noted in the descending duodenum.

A mild amount of fecal matter is seen within the descending colon.

**HOSPITAL NAME**

St. Catherine's Animal  
Hospital

**RADIOGRAPHIC DIAGNOSIS**

- Small intestinal maldigestion pattern with gastrointestinal aerophagia.
- No evidence of mechanical ileus.

**INTERPRETATION OF THE FINDINGS & FURTHER RECOMMENDATIONS****REFERRING VET**

Dr. Jui Gokhale

The radiographic presentation of the gastrointestinal tract suggests no evidence of mechanical ileus. Functional ileus is a potential. A mild amount of fecal matter was seen in the colon only. There was no evidence of a mass effect in or around the colon. Further definition by means of ultrasound and/or endoscopy could be considered in case of persisting or recurring clinical signs.

**INVOICE**

57500

**DATE**

3-27-23



**PATIENT**

Oreo Rong

**SPECIES**

Canine

**BREED**

Shih Tzu Mix

**SEX**

Male Neutered

**AGE**

5 Years

**INTERPRETED BY**

Nele Eley, DVM  
Dr. med. Vet. DipECVDI

**HOSPITAL NAME**

St. Catherine's Animal  
Hospital

**REFERRING VET**

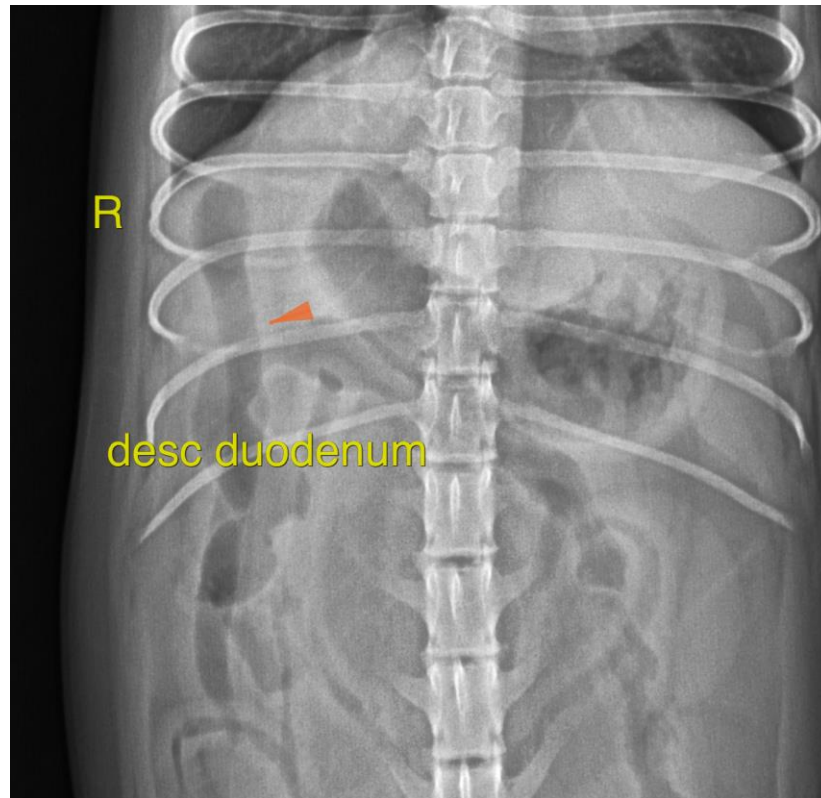
Dr. Jui Gokhale

**INVOICE**

57500

**DATE**

3-27-23



The information and recommendations provided are based on the images presented by the referring veterinarian/sonographer. No evaluation can be communicated regarding pathology that was not visible in the image/video clips provided.

Thank you for this referral. If the clinical or image interpretation does not parallel your findings or if I can be of any further assistance please contact me.

**Nele Eley**, DVM, Dr. med. vet., DipECVDI  
European Specialist in Veterinary Diagnostic Imaging, Cert. Radiology,  
Senior lecturer University of Giessen, Germany, Veterinary Faculty, Department of Radiology  
Nele.Eley@sonopath.com