



PATIENT PRESENTING CLINICAL SIGNS

Bentley Davis
SPECIES Canine
BREED Pomeranian Mix

Has been seen by 3 vets for shaking and coughing. Recently went to VSR (Veterinary Specialist of the Rockies). The licking is constant, and the cough comes and goes. She will lick the air or her lips but no where else on the body. She also has matts on her rear and she will not let Dawn touch her. She used keep herself clean like a cat. The cough is random. Someone will cough after drinking or eating. It sounds dry. She also shakes her ears a lot like her ears bother her. She doesn't typically scratch her ears. ** looking back in her history I see she had an episode of shaking and gagging last February that was treated with cerenia(antinausea) and buprenorphine(pain)**
 Abnormal PE/Chem/CBC/UA Results: tracheal palpation elicits cough slab fracture 208 few matts in rear

RADIOGRAPHIC STUDY OF THE THORAX & NECK

Right/left lateral and ventrodorsal views of the thorax and lateral and ventrodorsal views of the neck totaling 5 images available for review.

SEX

Spayed

AGE

7 Years, 6 Months

RADIOGRAPHIC FINDINGS

Variants of the cervical trachea diameter is noted in the right and left lateral views with reduction of the tracheal height by approximately 50% in the caudal cervical trachea on the right lateral view. The thoracic trachea presents within normal limits. No evidence of concurrent bronchial collapse is seen.

The lung presents a mild generalized bronchointerstitial pattern with even distribution throughout the lung. Occasional age related incidental pulmonary osteomas are seen.

The cardiac silhouette presents within normal limits. The vertebral heart score is 9.5. No evidence of abnormal mediastinal widening is noted.

The liver presents within normal limits.

The stomach is postprandial.

Number, alignment, and general anatomy of the cervical vertebrae present within normal limits.

No structural laryngeal abnormality is seen.

RADIOGRAPHIC DIAGNOSIS

- Dynamic tracheal disease.
- Mild generalized bronchointerstitial lung pattern.

INTERPRETATION OF THE FINDINGS & FURTHER RECOMMENDATIONS

The radiographic study supports the presence of dynamic tracheal disease which typically is associated with degenerative bronchomalacia. The dynamic collapse of the trachea appears to be limited to the cervical trachea. No concurrent bronchial collapse is seen.

The mild bronchointerstitial lung pattern may well be within age related normal limits. Low grade lower airway disease such as allergic / eosinophilic bronchopneumopathy or infectious bronchitis

INVOICE

57456

DATE

3-27-23

INTERPRETED BY

Nele Eley, DVM
 Dr. med. Vet. DipECVDI

HOSPITAL NAME

Elizabeth Animal
 Hospital

REFERRING VET

Kim Allyn, DVM



PATIENT

including viral, bacterial, and parasitic cannot be ruled out entirely.

Bentley Davis

SPECIES

Canine

BREED

Pomeranian Mix

SEX

Spayed

AGE

7 Years, 6 Months

INTERPRETED BY

Nele Eley, DVM
Dr. med. Vet. DipECVDI

HOSPITAL NAME

Elizabeth Animal
Hospital

REFERRING VET

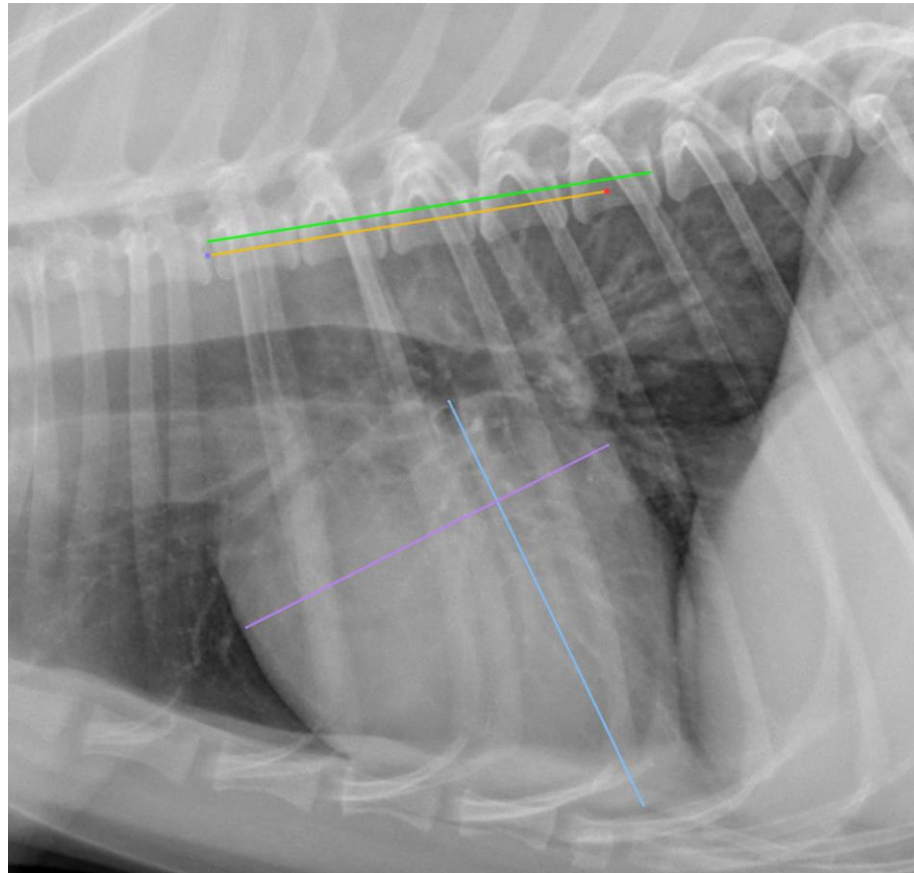
Kim Allyn, DVM

INVOICE

57456

DATE

3-27-23



The information and recommendations provided are based on the images presented by the referring veterinarian/sonographer. No evaluation can be communicated regarding pathology that was not visible in the image/video clips provided.

Thank you for this referral. If the clinical or image interpretation does not parallel your findings or if I can be of any further assistance please contact me.

Nele Eley, DVM, Dr. med. vet., DipECVDI
European Specialist in Veterinary Diagnostic Imaging, Cert. Radiology,
Senior lecturer University of Giessen, Germany, Veterinary Faculty, Department of Radiology
Nele.Eley@sonopath.com