



PATIENT

Claude Dippei

SPECIES

Canine

BREED

Chihuahua

SEX

MN

AGE

11

WEIGHT

3.7kg

INTERPRETED BY

Nele Eley (Ondreka),
DVM Dr. med. vet.,
DipECVDI

IMAGING PERFORMED BY

JAL

HOSPITAL NAME

Southern Oregon
Veterinary Specialty
Center

REFERRING VET

Fugazzi

INVOICE

74371

DATE

3-26-26

PRESENTING CLINICAL SIGNS

Owner reports a mandibular swelling first noticed about 1 month ago. Owner perceives it has enlarged, including since a biopsy last week. Claud is eating normally with normal energy. Increased dramatically in size.

COMPUTED TOMOGRAPHIC STUDY OF THE HEAD

Plain and post contrast studies are available for review.

COMPUTED TOMOGRAPHIC FINDINGS

A large aggressive osteolytic mass involving the entire left mandibular body from teeth 305 through 310 is seen. The mass measurements are approximately 5 x 2 x 2 cm. Accompanying soft tissue mass with nonuniform enhancement is seen. Loosening and displacement of associated teeth is noted. The osteolysis is permeative. Complete disruption of the cortical bone and amorphous periosteal new bone formation is seen. The transition zones are long and indistinct.

The left submandibular and retropharyngeal lymph nodes are mildly enlarged.

Generalized periodontal disease is noted.

COMPUTED TOMOGRAPHIC DIAGNOSIS

- Aggressive left mandibular neoplasia with extensive osteolysis, tooth involvement, and local invasion.
- Mild regional lymphadenopathy – may represent early metastatic or reactive change.

INTERPRETATION OF FINDINGS & FURTHER RECOMMENDATIONS

The CT findings are compatible with a biologically aggressive mandibular neoplasia. Differential diagnosis includes oral squamous cell carcinoma, fibrosarcoma, osteosarcoma, or chondrosarcoma.

The lymph node changes may be reactive in nature or represent early metastatic disease.

Histopathology would be required for tumor typing. Staging, including thoracic imaging and regional lymph node FNA or biopsy, can be considered as well as surgical consultation and pain management.



PATIENT

Claude Dippei

SPECIES

Canine

BREED

Chihuahua

SEX

MN

AGE

11

WEIGHT

3.7kg

INTERPRETED BY

Nele Eley (Ondreka),
DVM Dr. med. vet.,
DipECVDI

IMAGING PERFORMED BY

JAL

HOSPITAL NAME

Southern Oregon
Veterinary Specialty
Center

REFERRING VET

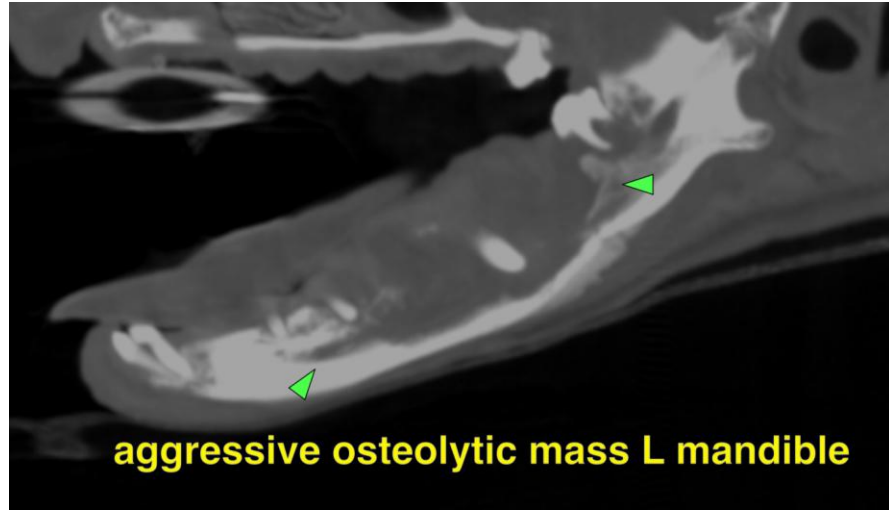
Fugazzi

INVOICE

74371

DATE

3-26-26



The information and recommendations provided are based on the images presented by the referring veterinarian. No evaluation can be communicated regarding pathology that was not visible in the image/video clips provided.

Thank you for this referral. If the clinical or image interpretation does not parallel your findings or if I can be of any further assistance please contact me.

Nele Eley (Ondreka), DVM, Dr. med. vet., DipECVDI
European Specialist in Veterinary Diagnostic Imaging, Cert. Radiology,
Senior lecturer University of Giessen/Germany, Veterinary Faculty, Department of Radiology.
info@sonopath.com