

**Diagnostic Imaging**

Veterinary CT, Ultrasound & Teletology Services  
veterinarian referral only

**PATIENT PRESENTING CLINICAL SIGNS**

- Finn Bressi
- focal seizures
  - Current medications: Denamarin, Fluoxetine

**SPECIES COMPUTED TOMOGRAPHIC STUDY OF THE HEAD**

Canine Plain and post contrast studies are available for review.

**COMPUTED TOMOGRAPHIC FINDINGS**

**BREED**

Terrier

The brain presents no deviation from normal anatomy and symmetry. The grey and white matter distinction and the neuroparenchymal attenuation are as expected. The distribution of contrast enhancement is within normal limits throughout the parenchyma and meninges. The ventricular system is non-dilated and within the limits of the expected volume and symmetry.

**SEX**

Male Neutered

Thin and smoothly folded conchae and turbinates with even smooth mucosal lining. The osseous lining of the nasal cavities is intact.

**AGE**

6Y

Both temporomandibular joints present congruent joint spaces with even subchondral bone surfaces and are considered within normal limits.

Both tympanic bullae are aerated, the mucosal lining is not seen, the bony wall is smooth and thin. The external auditory meatuses present within normal limits.

**INTERPRETED BY**

Nele Eley (Ondreka),  
DVM Dr. med. vet.,  
DipECVDI

The submandibular and medial retropharyngeal lymph nodes are small and elongated with a normal short-to-long-axis-ratio is < 0.5, the attenuation and contrast enhancement pattern is uniform.

The salivary glands present within normal limits.

Generalized periodontal disease with plaque accumulation is seen. Severe tooth and alveolar bone resorptions are noted at teeth 206, 207, and 208. Signs of chronic focal osteomyelitis are present around the distal root of the 208.

**HOSPITAL NAME**

Rockaway Animal  
Hospital

**COMPUTED TOMOGRAPHIC DIAGNOSIS**

- Normal CT presentation of the brain with no structural cause for seizures identified.
- Generalized periodontal disease including significant tooth and alveolar bone resorptions at 206-208.

**REFERRING VET**

Dr. Maniar

**INTERPRETATION OF FINDINGS & FURTHER RECOMMENDATIONS**

Intracranial lesions are not detected on CT. No structural cause for the seizural activity is identified. Focal seizures in middle aged dogs with normal brain CT can be due to a variety of causes including idiopathic/genetic epilepsy, metabolic/systemic causes, inflammatory/infectious causes, toxic, and less likely neoplastic. Consider MRI of the brain for higher sensitivity for small structural lesions or inflammatory changes should the seizural activity persist or deteriorate.

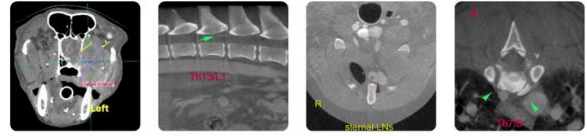
**INVOICE**

74358

**DATE**

3-25-26

Dental management with extraction of teeth 206-208 and management of generalized periodontal disease is recommended as well.



**Diagnostic Imaging**

Veterinary CT, Ultrasound & Telectology Services  
veterinarian referral only

SonoPath.com | info@sonopath.com | 1 (800) 838-4268  
141 Main St, Andover, NJ 07821

**PATIENT**

Finn Bressi

**SPECIES**

Canine

**BREED**

Terrier

**SEX**

Male Neutered

**AGE**

6Y

**INTERPRETED BY**

Nele Eley (Ondreka),  
DVM Dr. med. vet.,  
DipECVDI

**HOSPITAL NAME**

Rockaway Animal  
Hospital

**REFERRING VET**

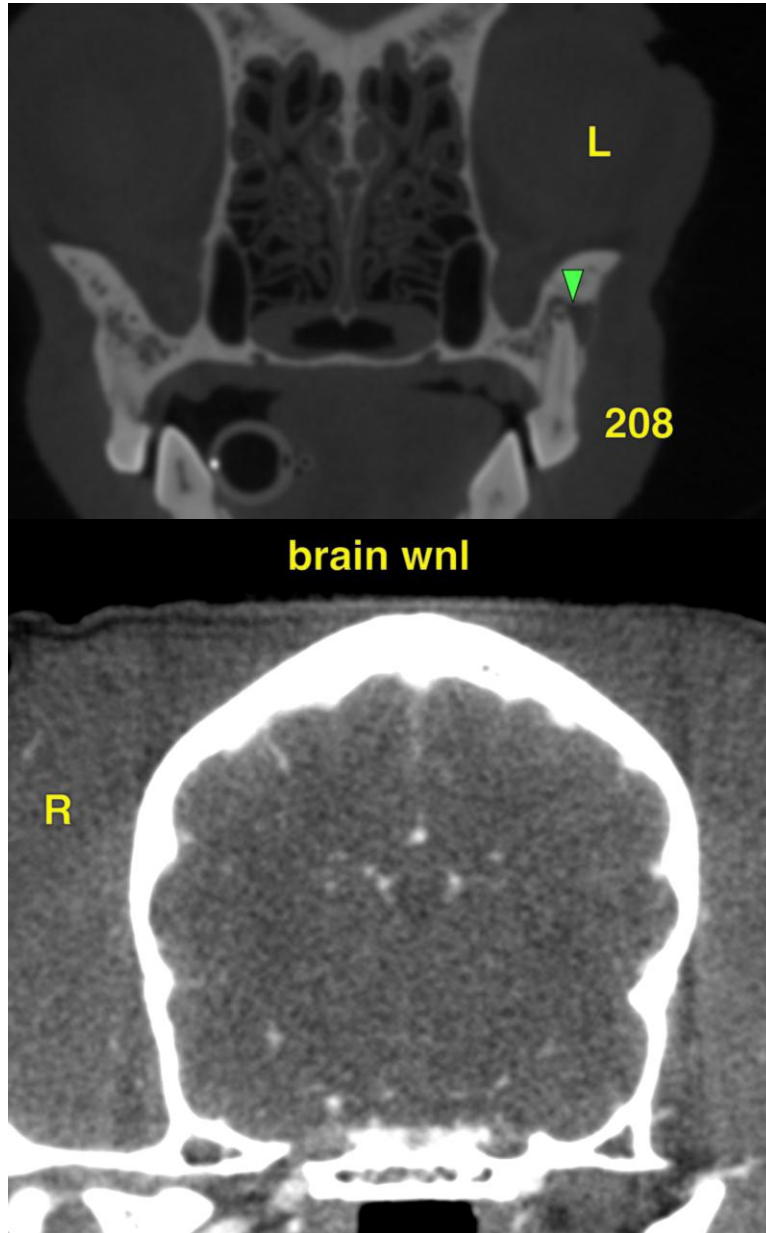
Dr. Maniar

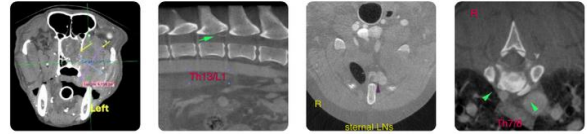
**INVOICE**

74358

**DATE**

3-25-26





**Diagnostic Imaging**

Veterinary CT, Ultrasound & Telectology Services  
veterinarian referral only

**PATIENT** The information and recommendations provided are based on the images presented by the referring veterinarian. No evaluation can be communicated regarding pathology that was not visible in the image/video clips provided.  
Finn Bressi

Thank you for this referral. If the clinical or image interpretation does not parallel your findings or if I can be of any further assistance please contact me.

**SPECIES**

Canine

**Nele Eley (Ondreka)**, DVM, Dr. med. vet., DipECVDI  
European Specialist in Veterinary Diagnostic Imaging, Cert. Radiology,  
Senior lecturer University of Giessen/Germany, Veterinary Faculty, Department of Radiology.

**BREED**

Terrier

[info@sonopath.com](mailto:info@sonopath.com)

**SEX**

Male Neutered

**AGE**

6Y

**INTERPRETED BY**

Nele Eley (Ondreka),  
DVM Dr. med. vet.,  
DipECVDI

**HOSPITAL NAME**

Rockaway Animal  
Hospital

**REFERRING VET**

Dr. Maniar

**INVOICE**

74358

**DATE**

3-25-26