



**PATIENT**

Zoe Aguilar

**PRESENTING CLINICAL SIGNS**

lost 15 lbs in 4 months , lose stool  
Abnormal PE/Chem/CBC/UA Results: elevated cPLI

**SPECIES**

Canine

**RADIOGRAPHIC STUDY OF THE ABDOMEN**

Right/left lateral and ventrodorsal views totaling 3 images available for review.

**BREED**

Pinscher Doberman

**RADIOGRAPHIC FINDINGS**

The patient is in thin body condition and deep chested.

Only a small part of the liver extends beyond the costal arch.

**SEX**

Female Spayed

The stomach contains a moderate amount of gas and gravel. No fluid distension of the stomach is seen.

The small intestinal loops are evenly distributed throughout the mid abdomen. No evidence of abnormal dilation, plication, or radiopaque foreign material is identified.

**AGE**

9 Years

The cecum and ascending colon contain a moderate amount of gas. A mild amount of fecal matter is seen in the descending colon. There is no evidence of abnormal dilation or a mass effect throughout the large intestine.

**INTERPRETED BY**

Nele Eley, DVM  
Dr. med. Vet. DipECVDI

Moderate lumbosacral spondylosis deformans is seen.

**RADIOGRAPHIC DIAGNOSIS**

- Gastric aerophagia and gravel.
- Degenerative lumbosacral stenosis.
- Thin body condition.

**HOSPITAL NAME**

St. Catherine's Animal  
Hospital

**INTERPRETATION OF THE FINDINGS & FURTHER RECOMMENDATIONS**

Presence of gastric gravel may be due to prior intake of mineral opaque material. The changes are not entirely typical for a gravel sign which would indicate partially impaired gastric outflow which, however, is not a primary suspicion here. No specific underlying cause of the clinical signs can be identified radiographically. There is no evidence of small intestinal ileus. Owing to the prolonged history, weight loss, and patient demographics, further definition by means of ultrasound would be recommended.

**REFERRING VET**

Dr. Boctor

**INVOICE**

51181

**DATE**

3-25-22



**PATIENT**

Zoe Aguilar

**SPECIES**

Canine

**BREED**

Pinscher Doberman

**SEX**

Female Spayed

**AGE**

9 Years

**INTERPRETED BY**

Nele Eley, DVM  
Dr. med. Vet. DipECVDI

**HOSPITAL NAME**

St. Catherine's Animal  
Hospital

**REFERRING VET**

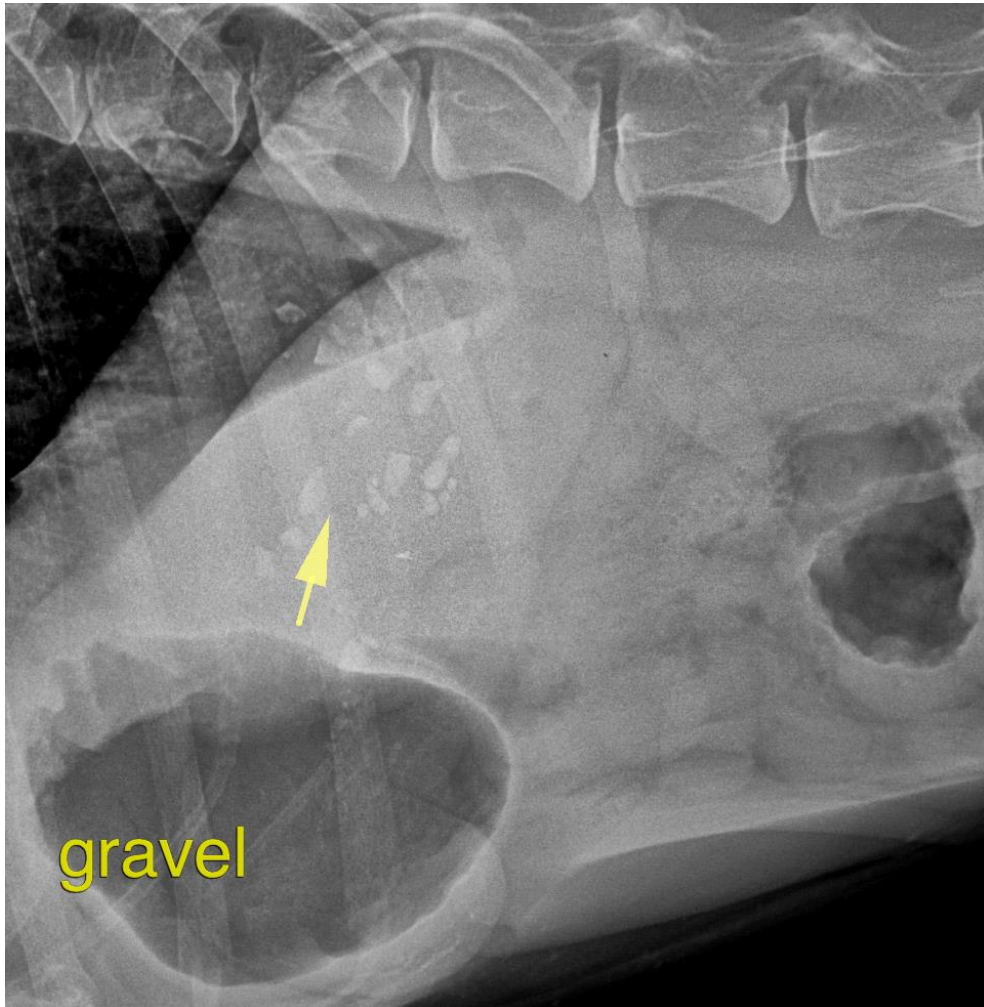
Dr. Boctor

**INVOICE**

51181

**DATE**

3-25-22



The information and recommendations provided are based on the images presented by the referring veterinarian/sonographer. No evaluation can be communicated regarding pathology that was not visible in the image/video clips provided.

Thank you for this referral. If the clinical or image interpretation does not parallel your findings or if I can be of any further assistance please contact me.

**Nele Eley**, DVM, Dr. med. vet., DipECVDI  
European Specialist in Veterinary Diagnostic Imaging, Cert. Radiology,  
Senior lecturer University of Giessen, Germany, Veterinary Faculty, Department of Radiology  
Nele.Eley@sonopath.com