



**PATIENT**

George Define

**PRESENTING CLINICAL SIGNS**

PU/PD for few weeks  
Abnormal PE/Chem/CBC/UA Results: unremarkable

**SPECIES**

Canine

**RADIOGRAPHIC STUDY OF THE THORAX & ABDOMEN**

Right/left lateral and ventrodorsal whole body views totaling 3 images available for review.

**BREED**

Chihuahua

**RADIOGRAPHIC FINDINGS**

The patient is mildly obese.

**SEX**

Male Neuter

**Thorax**

The surrounding bony structures are within normal limits.

The extrathoracic soft tissues present homogeneous without abnormalities.

**AGE**

10 Years

The heart is of normal size and shape and there is no evidence of cardiac chamber or vascular enlargement. The pulmonary vasculature is within normal limits. The vertebral heart score is 9.5

The cranial mediastinum presents the expected soft tissue opacity. The mediastinal width is less than twice the width of the vertebral column at the same level.

**INTERPRETED BY**

Nele Eley, DVM  
Dr. med. Vet. DipECVDI

The trachea is normal in diameter and presents the anticipated course. The luminal outline of the trachea is smooth.

A mild generalized bronchointerstitial lung pattern is seen with even distribution throughout the lung and considered within age related normal limits. There are occasional incidental age related pulmonary osteomas.

**HOSPITAL NAME**

St. Catherine's Animal  
Hospital

The diaphragm is well delineated with even surface and the expected mild cranial bulging of the diaphragmatic cupola.

**Abdomen**

**REFERRING VET**

Dr. Boctor

The surrounding bony structures are within normal limits.

No abnormalities of the extraabdominal soft tissues are noted. The abdominal wall is smooth and thin.

**INVOICE**

51182

The serosal detail is maintained throughout the peritoneal and retroperitoneal space.

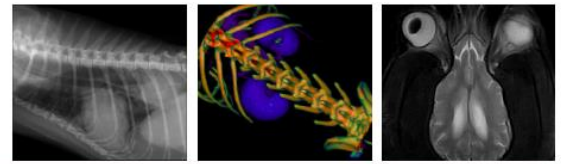
The liver is appropriate in position, size and presents uniform opacity.

**DATE**

3-25-22

The splenic head is in the anticipated position and within normal limits for size and opacity. The splenic body and tail are considered normal for position, size, shape and opacity.

Both kidneys are seen and present with normal size, shape, delineation and opacity. The urinary bladder is in its anticipated position. No radiopaque calculi are noted throughout the upper and



**PATIENT**

lower urinary tract.

George Define

The stomach is in its anticipated position and presents normal content.

**SPECIES**

The small intestinal loops are of even diameter and non-dilated, a small amount of gas is seen within the small intestinal loops and considered within normal limits.

Canine

The colon is seen in the expected position and presents with appropriate content.

**BREED**

**RADIOGRAPHIC DIAGNOSIS**

- Radiographically normal age related thorax and abdomen.

Chihuahua

**INTERPRETATION OF THE FINDINGS & FURTHER RECOMMENDATIONS**

**SEX**

No evidence of cardiovascular or bronchopulmonary pathology is identified radiographically. There is no evidence of abdominal mass effects or organomegaly. The abdominal serosal detail is maintained. The radiographic survey of the thorax and abdomen is considered benign. No direct underlying cause of the clinical signs can be identified and further laboratory workup as well as abdominal ultrasound could be considered for further definition.

Male Neuter

**AGE**

10 Years

**INTERPRETED BY**

Nele Eley, DVM  
Dr. med. Vet. DipECVDI

**HOSPITAL NAME**

St. Catherine's Animal  
Hospital

**REFERRING VET**

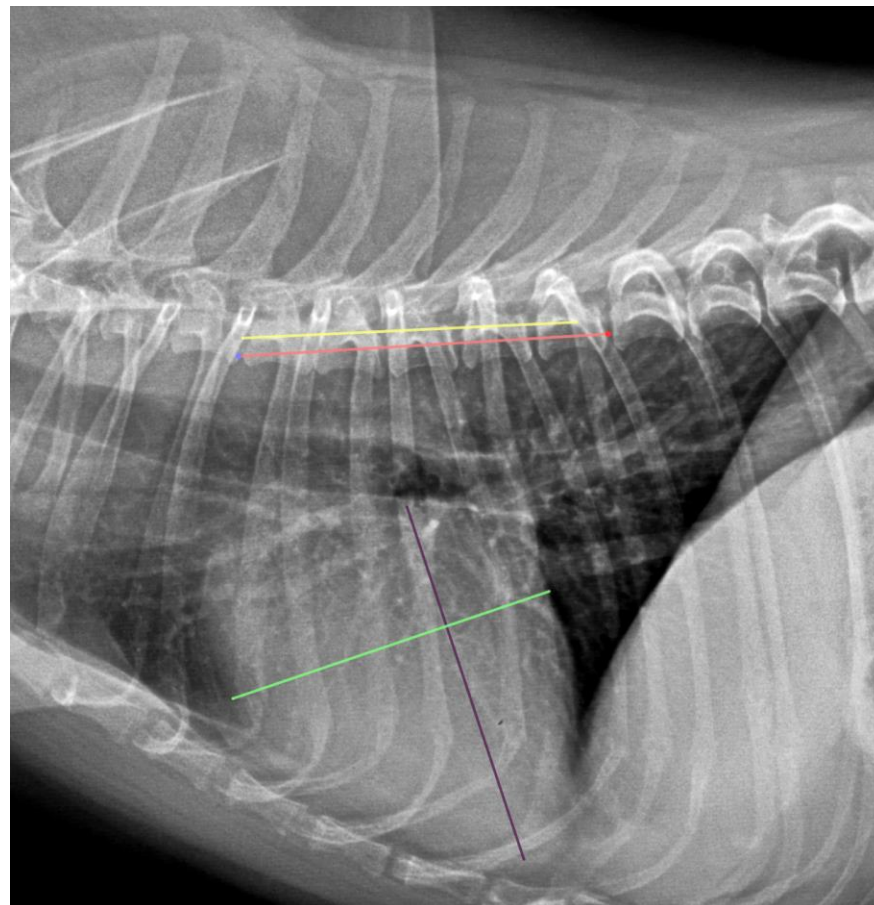
Dr. Boctor

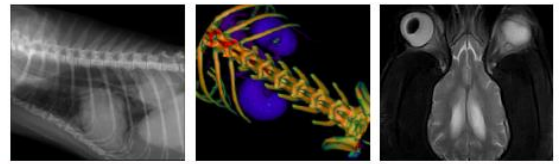
**INVOICE**

51182

**DATE**

3-25-22





### PATIENT

George Define

The information and recommendations provided are based on the images presented by the referring veterinarian/sonographer. No evaluation can be communicated regarding pathology that was not visible in the image/video clips provided.

### SPECIES

Canine

Thank you for this referral. If the clinical or image interpretation does not parallel your findings or if I can be of any further assistance please contact me.

### BREED

Chihuahua

**Nele Eley**, DVM, Dr. med. vet., DipECVDI  
European Specialist in Veterinary Diagnostic Imaging, Cert. Radiology,  
Senior lecturer University of Giessen, Germany, Veterinary Faculty, Department of Radiology  
Nele.Eley@sonopath.com

### SEX

Male Neuter

### AGE

10 Years

### INTERPRETED BY

Nele Eley, DVM  
Dr. med. Vet. DipECVDI

### HOSPITAL NAME

St. Catherine's Animal  
Hospital

### REFERRING VET

Dr. Boctor

### INVOICE

51182

### DATE

3-25-22