



PATIENT PRESENTING CLINICAL SIGNS

Brutus Wilson chronic cough for a few weeks now, dry, happens and night most of the time, heart sounds normal
Abnormal PE/Chem/CBC/UA Results: no bloodwork done

SPECIES RADIOGRAPHIC STUDY OF THE THORAX

Canine Right/left lateral and ventrodorsal views totaling 3 images available for review.

BREED RADIOGRAPHIC FINDINGS

Pug Mix Two fat / soft tissue opacities are seen ventral of the caudal thoracic wall on the right lateral view.

SEX
MN The degree of pulmonary inflation is fair at best upon inspiration and expiration. Upon inspiration, partial collapse of the intrathoracic trachea can be seen as well as a soft tissue opacity in the caudodorsal thorax suggesting potential for a sliding hiatal hernia. Far cranial excursion of the diaphragm is seen. The lung presents a moderate bronchointerstitial pattern which, however, may be enhanced by the poor inflation.

Abundance of subcutaneous mediastinal and pericardial fat is seen.

AGE
11 Years No overt enlargement of the cardiac silhouette is noted.

RADIOGRAPHIC DIAGNOSIS

- INTERPRETED BY**
Nele Eley, DVM
Dr. med. Vet. DipECVDI
- Suspect chronic upper airway restriction.
 - Dynamic trachea disease.
 - Suspect sliding hiatal hernia.
 - Moderate bronchointerstitial lung pattern.
 - Thoracic wall lipoma versus cranioventral abdominal hernia.

HOSPITAL NAME INTERPRETATION OF THE FINDINGS & FURTHER RECOMMENDATIONS

Sylvan Lake Veterinary Clinic
REFERRING VET
Dr. Babette Baskerville

Most of the radiographic findings are compatible with or a consequence of brachycephalic upper airway syndrome such as the collapse of the thoracic trachea and the sliding hiatal hernia. A mild to moderate bronchointerstitial lung pattern is noted which may be enhanced by the poor degree of pulmonary inflation. However, chronic lower airway disease such as irritant/allergic bronchopneumopathy versus infectious bronchitis such as viral, bacterial, and less likely parasitic, or protozoal cannot be ruled out. Consider upper and lower airway endoscopy with airway sampling for further definition.

INVOICE

51163

DATE

3-25-22



PATIENT

Brutus Wilson

SPECIES

Canine

BREED

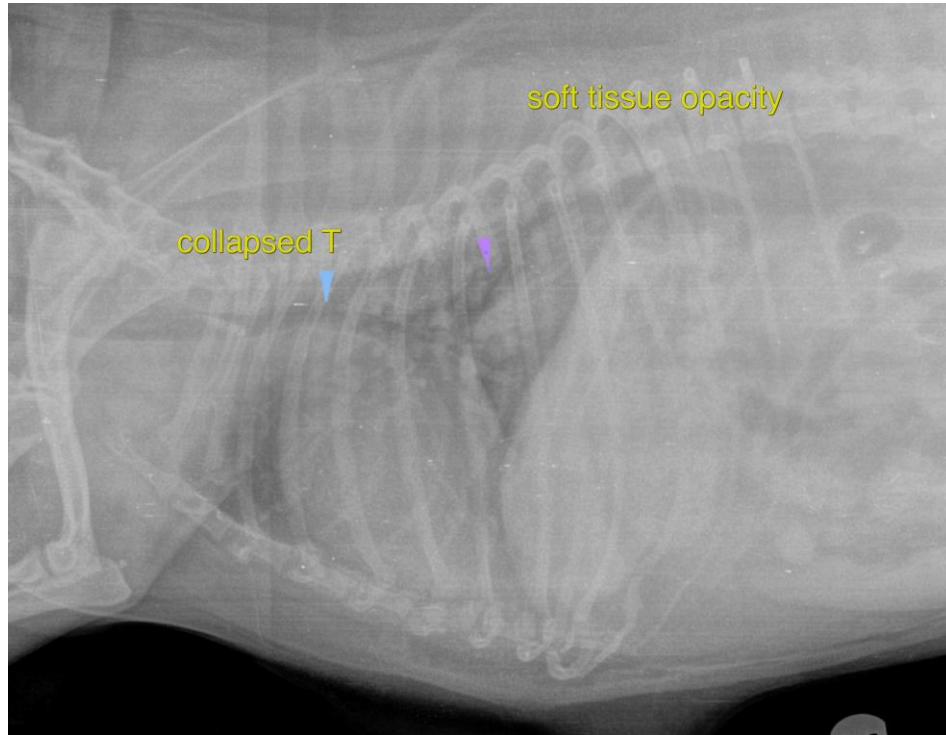
Pug Mix

SEX

MN

AGE

11 Years



INTERPRETED BY

Nele Eley, DVM
Dr. med. Vet. DipECVDI

The information and recommendations provided are based on the images presented by the referring veterinarian/sonographer. No evaluation can be communicated regarding pathology that was not visible in the image/video clips provided.

HOSPITAL NAME

Sylvan Lake
Veterinary Clinic

Thank you for this referral. If the clinical or image interpretation does not parallel your findings or if I can be of any further assistance please contact me.

Nele Eley, DVM, Dr. med. vet., DipECVDI
European Specialist in Veterinary Diagnostic Imaging, Cert. Radiology,
Senior lecturer University of Giessen, Germany, Veterinary Faculty, Department of Radiology
Nele.Eley@sonopath.com

REFERRING VET

Dr. Babette
Baskerville

INVOICE

51163

DATE

3-25-22