



PATIENT

Hank Tankerton

SPECIES

K9

BREED

Great Pyrenees

SEX

MN

AGE

6.75

WEIGHT

54kg

INTERPRETED BY

Nele Eley (Ondreka),
DVM Dr. med. vet.,
DipECVDI

IMAGING PERFORMED BY

James Gaynor

HOSPITAL NAME

Buffalo Mountain
Animal Hospital

REFERRING VET

James Gaynor

INVOICE

74326

DATE

3-24-26

PRESENTING CLINICAL SIGNS

- 2 month hx of Left rear lameness

Abnormal PE/Chem/CBC/UA Results: Exam: Left knee extension pain; mild cranial drawer
Radiographs: left knee effusion, OA

ULTRASONOGRAPHIC FINDINGS

Left Stifle

Moderate anechoic effusion is seen in the supra- and infra-patellar recesses of the left stifle joint. Mild periarticular osteophyte formation is present.

Disrupted cranial cruciate ligament fibers are seen at the intercondylar eminence of the tibia surrounded by a halo of anechoic effusion.

The medial meniscus is normal in position, shape, and echogenicity.

Right Stifle

Mild anechoic effusion is present.

The cranial cruciate ligament appears intact with normal fiber pattern and delineation.

The medial meniscus is normal in position, shape, and echogenicity.

ULTRASONOGRAPHIC DIAGNOSIS

- CCL injury of the left stifle with mild to moderate stifle osteoarthritis and effusion.
- Mild effusion in the right stifle joint without evidence of CCL or meniscal injury.

INTERPRETATION OF FINDINGS & FURTHER RECOMMENDATIONS

The disruption of the CCL fibers in the left stifle joint correlates with the clinical lameness and positive cranial drawer noted on clinical examination. The medial meniscus appears intact based on the ultrasonographic presentation suggesting no concurrent meniscal injury at this time, though follow up evaluation may be warranted. Early degenerative changes are consistent with chronic joint stress and degeneration. Surgical stabilization is recommended such as by TPLO, TTA, or other repair technique based on the surgeon's preference to restore joint stability and reduce progression of osteoarthritis and prevent secondary medial meniscal injury.



PATIENT

Hank Tankerton

SPECIES

K9

BREED

Great Pyrenees

SEX

MN

AGE

6.75

WEIGHT

54kg

INTERPRETED BY

Nele Eley (Ondreka),
DVM Dr. med. vet.,
DipECVDI

IMAGING PERFORMED BY

James Gaynor

HOSPITAL NAME

Buffalo Mountain
Animal Hospital

REFERRING VET

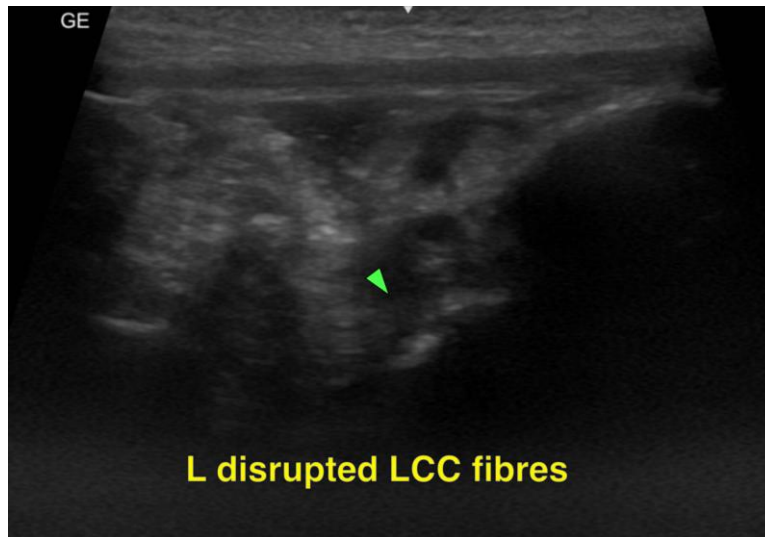
James Gaynor

INVOICE

74326

DATE

3-24-26



The information and recommendations provided are based on the images presented by the referring veterinarian. No evaluation can be communicated regarding pathology that was not visible in the image/video clips provided.

Thank you for this referral. If the clinical or image interpretation does not parallel your findings or if I can be of any further assistance please contact me.

Nele Eley (Ondreka), DVM, Dr. med. vet., DipECVDI

European Specialist in Veterinary Diagnostic Imaging, Cert. Radiology,
Senior lecturer University of Giessen/Germany, Veterinary Faculty, Department of Radiology.
info@sonopath.com