

**PATIENT**

Coco Magdziak

PRESENTING CLINICAL SIGNS

Coco came in today for having yellowish discharge on and off for 2 weeks . drinks and peeing more. the owner believe that her abdomen is slightly bigger last week.

Abnormal PE/Chem/CBC/UA Results: WBC 28.90 6.00-17.00 LYM 5.31 1.00-4.80 NEU 21.89 3.00-12.00 EOS 0.86 0.00-0.80 RBC 5.47 5.50-8.50 BUN 11.0 2-9 CRE 146 27.0-124 TP 83 54.0-82.0

SPECIES

Canine

RADIOGRAPHIC STUDY OF THE ABDOMEN

Right/left lateral and ventrodorsal views totaling 3 images available for review.

BREED

Shih Tzu

RADIOGRAPHIC FINDINGS

A large tubular soft tissue opacity with mass effect is seen in the caudal abdomen and can be traced from the pelvic inlet dorsal to the urinary bladder. The opacity is situated between the descending colon and the urinary bladder and causes dorsal deviation of the descending colon and rectum. Small mineral opacities superimpose onto the urinary bladder in the left lateral view. However, appear to be associated with the ventral abdominal wall rather than with the abdomen in the left lateral view.

SEX

F

AGE

12 Years

Crowding of the intestine is noted in the mid abdomen owing to the mass effect in the caudal abdomen.

The mamils are prominent.

Moderate generalized osteopenia is seen.

INTERPRETED BY

Nele Eley, DVM
Dr. med. Vet. DipECVDI

RADIOGRAPHIC DIAGNOSIS

- Uterine enlargement with mass effect and reduced serosal detail.

HOSPITAL NAME

Brittany Glen Animal
Hospital

INTERPRETATION OF THE FINDINGS & FURTHER RECOMMENDATIONS

The radiographic findings are highly suggestive for uterine enlargement with mass effect. Differential diagnosis includes uterine / cervical neoplasia, pyometra complex, and other urogenital soft tissue mass. Further definition by means of ultrasound or CT is strongly recommended if not performed already.

REFERRING VET

Dr. Boktor

INVOICE

51152

DATE

3-24-22



PATIENT

Coco Magdziak

SPECIES

Canine

BREED

Shih Tzu

SEX

F

AGE

12 Years

INTERPRETED BY

Nele Eley, DVM
Dr. med. Vet. DipECVDI

HOSPITAL NAME

Brittany Glen Animal
Hospital

REFERRING VET

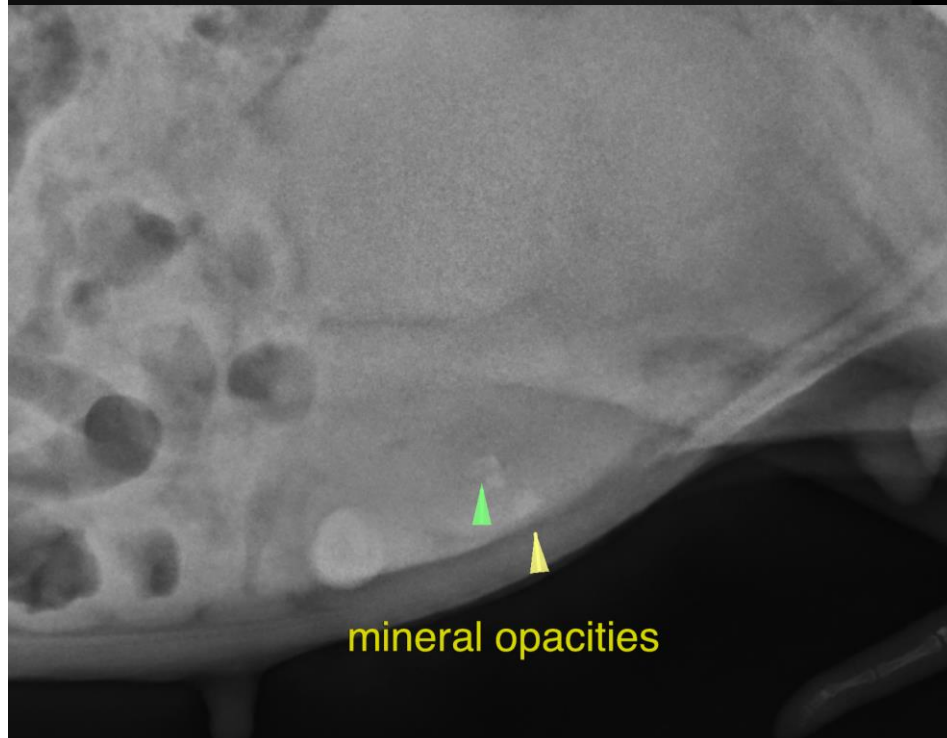
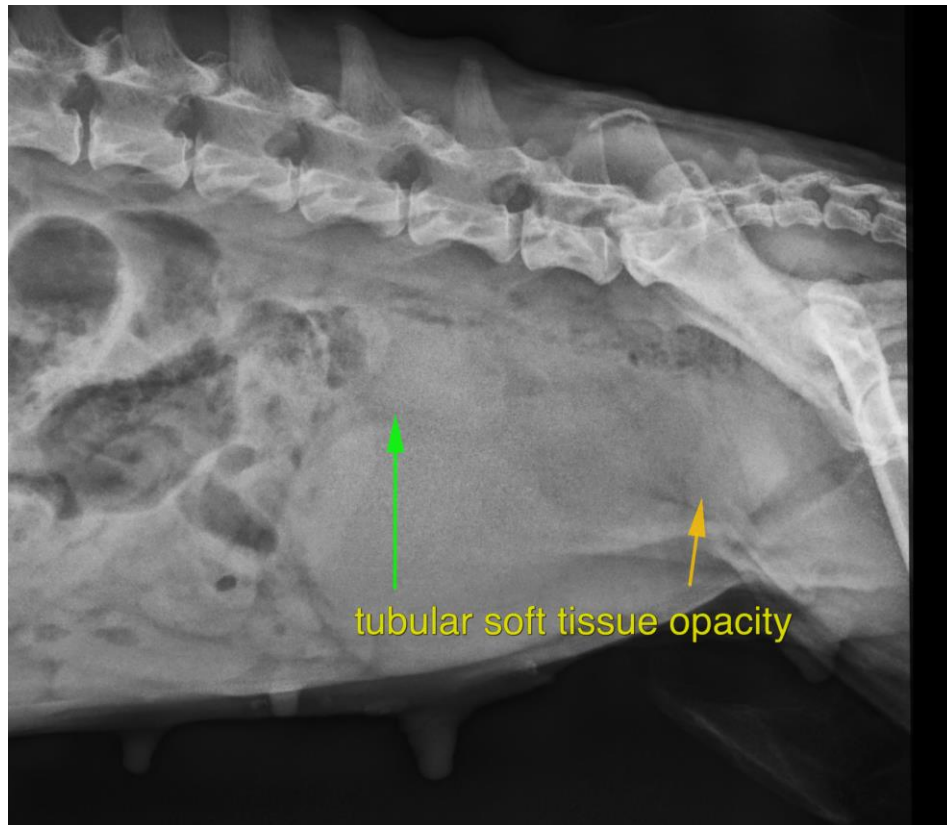
Dr. Boktor

INVOICE

51152

DATE

3-24-22





PATIENT

Coco Magdziak

The information and recommendations provided are based on the images presented by the referring veterinarian/sonographer. No evaluation can be communicated regarding pathology that was not visible in the image/video clips provided.

SPECIES

Canine

Thank you for this referral. If the clinical or image interpretation does not parallel your findings or if I can be of any further assistance please contact me.

BREED

Shih Tzu

Nele Eley, DVM, Dr. med. vet., DipECVDI
European Specialist in Veterinary Diagnostic Imaging, Cert. Radiology,
Senior lecturer University of Giessen, Germany, Veterinary Faculty, Department of Radiology
Nele.Eley@sonopath.com

SEX

F

AGE

12 Years

INTERPRETED BY

Nele Eley, DVM
Dr. med. Vet. DipECVDI

HOSPITAL NAME

Brittany Glen Animal
Hospital

REFERRING VET

Dr. Boktor

INVOICE

51152

DATE

3-24-22