

**PATIENT**

Bamboo Liu

**SPECIES**

Feline

**BREED**

Devon Rex

**SEX**

MN

**AGE**

10 Months

**INTERPRETED BY**Nele Eley, DVM  
Dr. med. Vet. DipECVDI**HOSPITAL NAME**Animal Health  
Partners**REFERRING VET**

Dr. Marchal

**INVOICE**

51147

**DATE**

3-24-22

**PRESENTING CLINICAL SIGNS**

Bamboo, a 10 months old, MN Devon Rex, presented to the AHP Neurology Service on March 19, 2022 for evaluation of vestibular signs. He was seen at Toronto Veterinary Emergency Hospital on March 19, 2022 for further evaluation of anorexia and lethargy. Bamboo's owners report that Bamboo was neutered about 1 month ago, following which he became ataxic. Apart from being ataxic Bamboo was otherwise acting normally. This progressed to him not being interested in food and has not been able to walk as of yesterday. Bloodwork was performed 1 month ago prior to spay and was unremarkable. On assessment at TVEH, he was on lateral recumbency, non-ambulatory, showed rotatory nystagmus; had decreased nasal septal response bilaterally. He was treated with maropitant, ampicillin and IVF and transferred to AHP neurology service.

**MAGNETIC RESONANCE IMAGING STUDY OF THE BRAIN**

T2, T2 star, diffusion weighted plus ADC, FLAIR, and T1-plain and post contrast studies available for review.

**MAGNETIC RESONANCE IMAGING FINDINGS**

The MRI study reveals moderate generalized ventriculomegaly with secondary mass effect including cerebellar herniation into the foramen magnum as well as caudal transtentorial herniation of the quadrigeminal plate, compression of the cerebellum and brainstem by the dilated fourth ventricle, and intermedullary T2 hyperintensity within the upper cervical spinal cord consistent with syringomyelia. The CSF signal appears to be slightly enhanced on the FLAIR studies. The post-contrast study reveals extensive ependymal contrast enhancement within the lateral third and fourth ventricles as well as meningeal enhancement most apparent circumferential to the brainstem and craniocervical spine cord.

**MAGNETIC RESONANCE IMAGING DIAGNOSIS**

- Hydrocephalus internus with increased intracranial pressure and foraminal as well as subtentorial hernia and syringomyelia.
- Extensive leptomeningopathy and ependymopathy.

**INTERPRETATION OF THE FINDINGS & FURTHER RECOMMENDATIONS**

The MRI findings are highly suggestive for leptomeningitis and ependymal vasculitis with secondary ventriculomegaly and mass effect. FIP is the most likely underlying cause of the pertinent MRI findings. Other causes of meningitis and encephalitis such as toxoplasma, cryptococcus, feline leukemia virus, feline immunodeficiency virus, rabies, and other cannot be ruled out entirely. Correlation with CSF analysis and other laboratory values would be ideal. Caution, however, must be applied when attempting to aspirate CSF in the cervical region owing to the cerebellar herniation.



**PATIENT**

Bamboo Liu

**SPECIES**

Feline

**BREED**

Devon Rex

**SEX**

MN

**AGE**

10 Months

**INTERPRETED BY**

Nele Eley, DVM  
Dr. med. Vet. DipECVDI

**HOSPITAL NAME**

Animal Health  
Partners

**REFERRING VET**

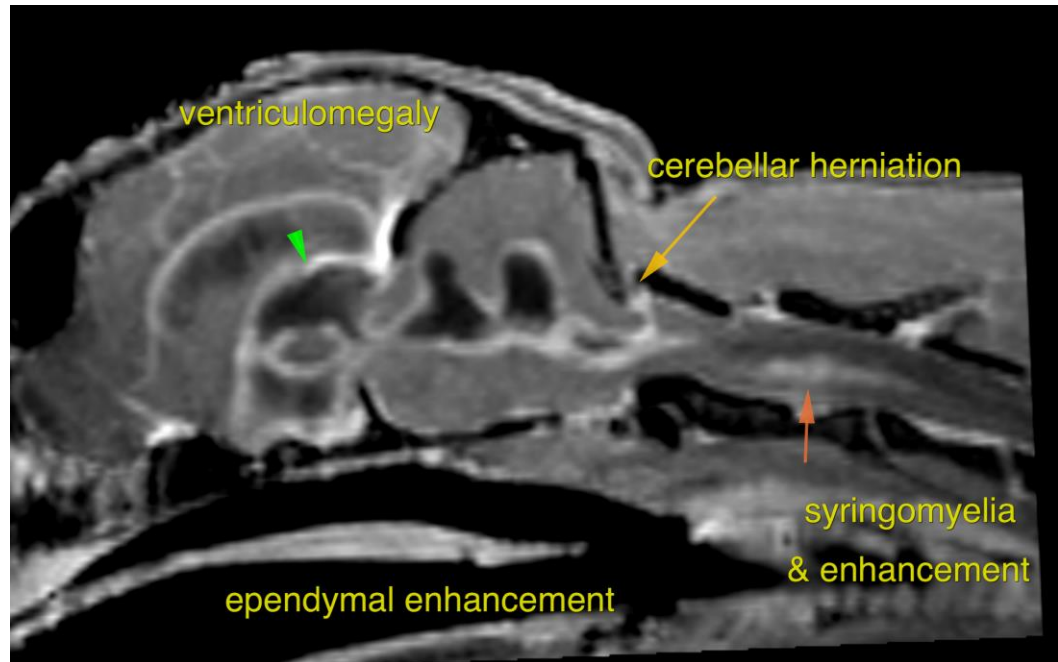
Dr. Marchal

**INVOICE**

51147

**DATE**

3-24-22



The information and recommendations provided are based on the images presented by the referring veterinarian/sonographer. No evaluation can be communicated regarding pathology that was not visible in the image/video clips provided.

Thank you for this referral. If the clinical or image interpretation does not parallel your findings or if I can be of any further assistance please contact me.

**Nele Eley**, DVM, Dr. med. vet., DipECVDI  
European Specialist in Veterinary Diagnostic Imaging, Cert. Radiology,  
Senior lecturer University of Giessen, Germany, Veterinary Faculty, Department of Radiology  
Nele.Eley@sonopath.com