



PATIENT

Baby Smith

PRESENTING CLINICAL SIGNS

abnormal sternum with caudal portion/section angled into thorax which then turns back to ventrum (like a sideways letter J), heart appears shifted to left, stomach appears large/filled with food, diaphragm difficult to identify clearly across thorax

SPECIES

Feline

RADIOGRAPHIC STUDY OF THE THORAX

Right/left lateral and ventrodorsal views totaling 3 images available for review.

BREED

Domestic Medium Hair

RADIOGRAPHIC FINDINGS

Severe dorsal deviation of the 6th and 7th sternebrae creates a concave contour of the caudoventral thoracic wall with inward rotation of the sternum. The thoracic height is reduced by 70% at maximum. Leftward deviation of the cardiac silhouette is noted which appears to be pushed against the left lateral thoracic wall. There is lobar atelectasis of the caudal subsegment of the left cranial lung lobe and reduced left lung volume.

SEX

Female

The aerated lung presents within age related normal limits.

AGE

19 Weeks

Marked cranial deviation of the diaphragmatic cupola is seen on both the lateral and ventrodorsal images.

The stomach contains a large amount of fluid and gas.

INTERPRETED BY

Nele Eley, DVM
Dr. med. Vet. DipECVDI

RADIOGRAPHIC DIAGNOSIS

- Moderate to severe pectus excavatum with cardiac shift and lobar pulmonary atelectasis.
- Fluid distended stomach.
- Cranial deviation of the diaphragmatic cupola.

HOSPITAL NAME

MYAH

INTERPRETATION OF THE FINDINGS & FURTHER RECOMMENDATIONS

The radiographic study reveals moderate to severe pectus excavatum which represents a congenital malformation. The malformation results in limited thoracic volume and a mass effect onto the cardiac silhouette which is shifted towards the left side. Moreover, compression atelectasis of the left cranial lung lobe is noted. The deformity may be associated with cardiac disease and exercise intolerance owing to limitations of the respiratory motion.

REFERRING VET

Rachel Eddleman

The cranial deviation of the diaphragmatic cupola is likely secondary to the inward rotation of the sternum; however, pectus excavatum can be associated with congenital diaphragmatic defects. At this time, no overt diaphragmatic hernia is seen. Severity of the malformation can increase during skeletal development; however, the malformation typically seizes and remains stable after skeletal maturity is reached. Bandage orthosis, vacuum device treatment, as well as surgery all have been described but typically are limited in success with increasing skeletal maturity.

INVOICE

51145

DATE

3-24-22



PATIENT

Baby Smith

SPECIES

Feline

BREED

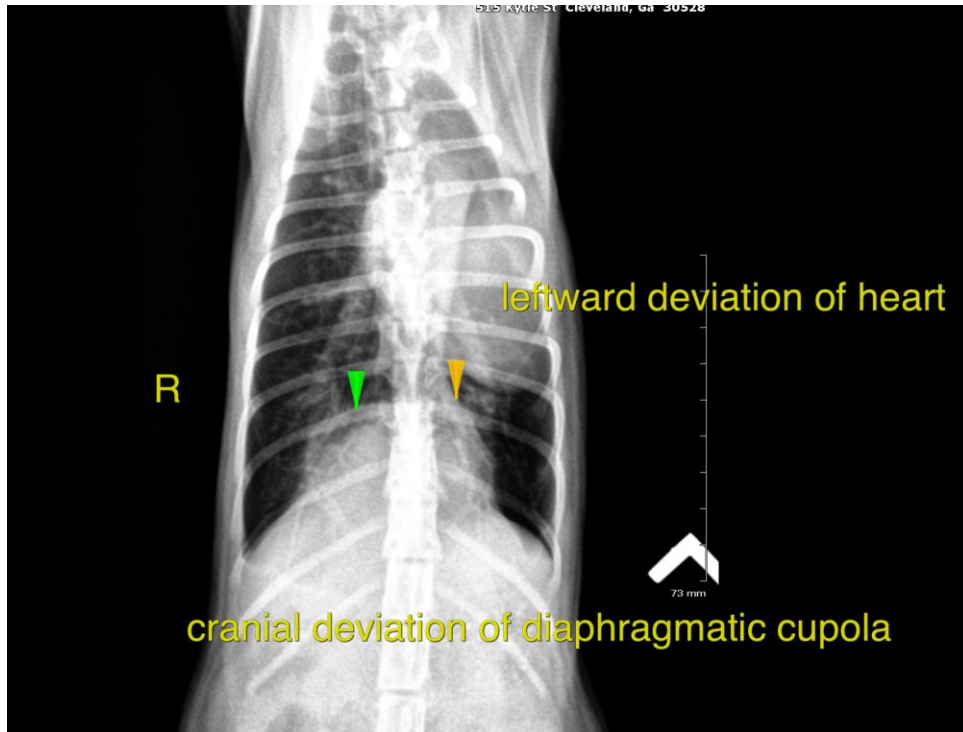
Domestic Medium
Hair

SEX

Female

AGE

19 Weeks



INTERPRETED BY

Nele Eley, DVM
Dr. med. Vet. DipECVDI

The information and recommendations provided are based on the images presented by the referring veterinarian/sonographer. No evaluation can be communicated regarding pathology that was not visible in the image/video clips provided.

HOSPITAL NAME

MYAH

Thank you for this referral. If the clinical or image interpretation does not parallel your findings or if I can be of any further assistance please contact me.

Nele Eley, DVM, Dr. med. vet., DipECVDI
European Specialist in Veterinary Diagnostic Imaging, Cert. Radiology,
Senior lecturer University of Giessen, Germany, Veterinary Faculty, Department of Radiology
Nele.Eley@sonopath.com

REFERRING VET

Rachel Eddleman

INVOICE

51145

DATE

3-24-22