



## PATIENT

Toby Lopez

## SPECIES

Canine

## BREED

Australian Shepherd

## SEX

M

## AGE

4Y

## WEIGHT

n/a

## INTERPRETED BY

Nele Eley (Ondreka),  
DVM Dr. med. vet.,  
DipECVDI

## IMAGING PERFORMED BY

Kerri Becker

## HOSPITAL NAME

All Creatures Denville

## REFERRING VET

Dr. Silas

## INVOICE

74301

## DATE

3-23-26

## PRESENTING CLINICAL SIGNS

- Limping left back leg worse.
- patella, cranial draw test possible partial acl.

## ULTRASONOGRAPHIC FINDINGS

### Left Stifle

The patella appears to exhibit medial luxation. Moderate osteoarthritic changes are present including periarticular osteophytes formation, synovial thickening, and joint effusion.

The cranial cruciate ligament appears continuous and intact with no ultrasonographic signs of tearing.

The medial meniscus is normal in position, shape, and echogenicity.

### Right Stifle

The patella appears normally positioned. Minimal joint effusion is noted.

The cranial cruciate ligament and medial meniscus appear normal. No signs of patella luxation, cranial cruciate ligament injury, or meniscal injury is seen.

## ULTRASONOGRAPHIC DIAGNOSIS

### Left Stifle:

- Medial patella luxation with moderate osteoarthritis.
- CCL and medial meniscus normal.

### Right Stifle:

- Normal except for minimal effusion – likely reactive.

## INTERPRETATION OF FINDINGS & FURTHER RECOMMENDATIONS

The ultrasonographic findings do not support the presence of CCL injury in the left stifle at this point. Moderate osteoarthritic changes are seen along with presumed chronic medial patella luxation. Surgical stabilization can be considered should patella luxation be of clinical significance. Clinical correlation is required.



## PATIENT

Toby Lopez

## SPECIES

Canine

## BREED

Australian Shepherd

## SEX

M

## AGE

4Y

## WEIGHT

n/a

## INTERPRETED BY

Nele Eley (Ondreka),  
DVM Dr. med. vet.,  
DipECVDI

## IMAGING PERFORMED BY

Kerri Becker

## HOSPITAL NAME

All Creatures Denville

## REFERRING VET

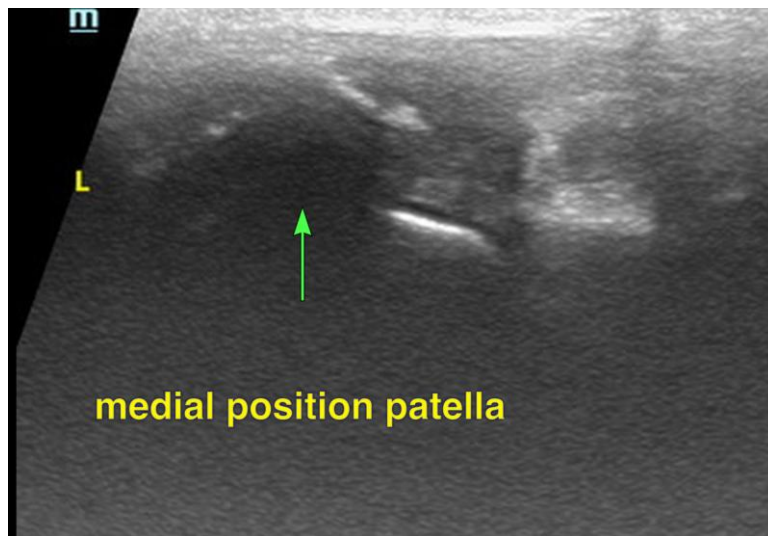
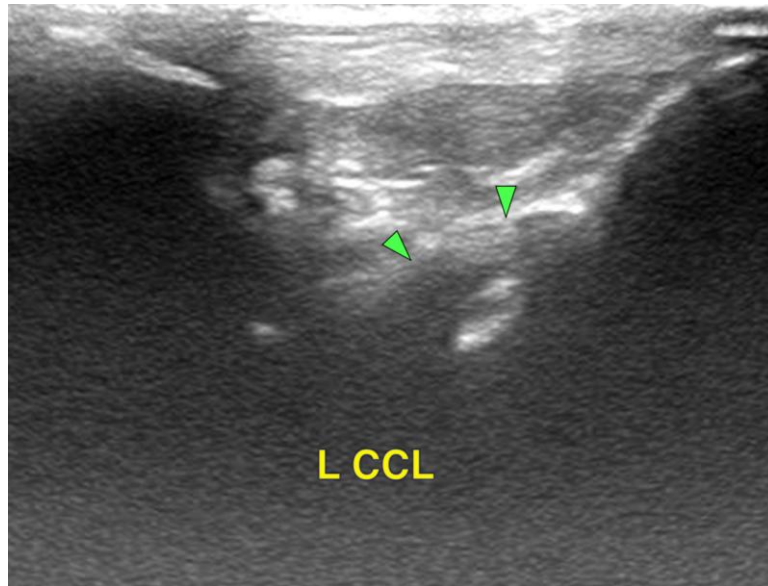
Dr. Silas

## INVOICE

74301

## DATE

3-23-26





## PATIENT

Toby Lopez

## SPECIES

Canine

## BREED

Australian Shepherd

## SEX

M

## AGE

4Y

## WEIGHT

n/a

## INTERPRETED BY

Nele Eley (Ondreka),  
DVM Dr. med. vet.,  
DipECVDI

## IMAGING PERFORMED BY

Kerri Becker

## HOSPITAL NAME

All Creatures Denville

## REFERRING VET

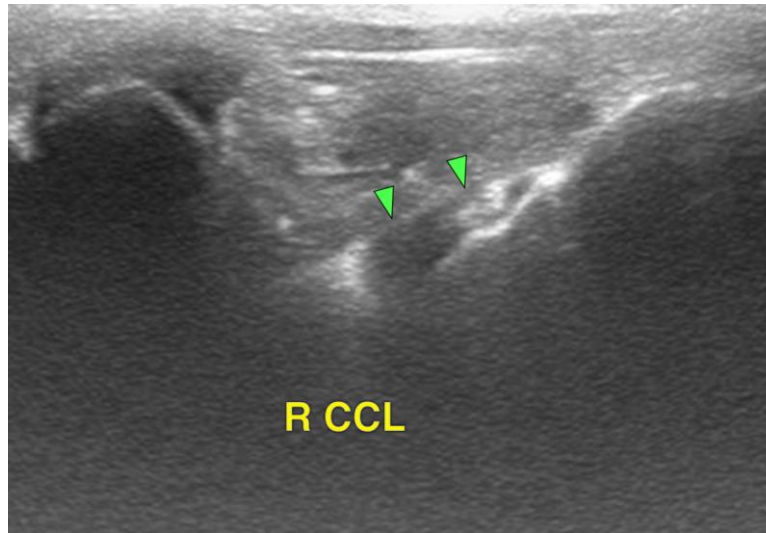
Dr. Silas

## INVOICE

74301

## DATE

3-23-26



The information and recommendations provided are based on the images presented by the referring veterinarian. No evaluation can be communicated regarding pathology that was not visible in the image/video clips provided.

Thank you for this referral. If the clinical or image interpretation does not parallel your findings or if I can be of any further assistance please contact me.

**Nele Eley (Ondreka)**, DVM, Dr. med. vet., DipECVDI  
European Specialist in Veterinary Diagnostic Imaging, Cert. Radiology,  
Senior lecturer University of Giessen/Germany, Veterinary Faculty, Department of Radiology.  
[info@sonopath.com](mailto:info@sonopath.com)