

**PATIENT**

Shiba Pina Bond

PRESENTING CLINICAL SIGNS

Symptoms of hind end pain with marked discomfort on palpation of the left iliopsoas tendon.

SPECIES

Canine

ULTRASONOGRAPHIC FINDINGS**Left Iliopsoas**

The left psoas major tendon is well delineated and presents uniform internal echoarchitecture and echogenicity. The attachment to the lesser trochanter of the femur is smooth. No evidence of new bone formation or fluid accumulation is seen. The musculotendinous junction presents within normal limits. The hyperechoic tendon fibers blend smoothly into the hypoechoic muscle tissue. The visible muscular portion presents within normal limits.

BREED

Shiba Inu

The visible parts of the coxofemoral joint presents within normal limits.

SEX

FS

Right Iliopsoas

The right psoas major tendon is well delineated and presents uniform internal echoarchitecture and echogenicity. The attachment to the lesser trochanter of the femur is smooth. No evidence of new bone formation or fluid accumulation is seen. The musculotendinous junction presents within normal limits. The hyperechoic tendon fibers blend smoothly into the hypoechoic muscle tissue. The visible muscular portion presents within normal limits.

AGE

6 Years

The visible parts of the coxofemoral joint presents within normal limits.

INTERPRETED BYNele Eley, DVM
Dr. med. Vet. DipECVDI**ULTRASONOGRAPHIC DIAGNOSIS**

- Normal ultrasonographic presentation of the iliopsoas in both hind limbs.
- Normal ultrasonographic presentation of both coxofemoral joints.

HOSPITAL NAMEPoints East West
Veterinary Services**INTERPRETATION OF THE FINDINGS & FURTHER RECOMMENDATIONS**

The ultrasonographic examination was not able to reveal structural abnormality within the iliopsoas in both hind limbs which renders acute and chronic macromorphological injury unlikely. However, early stages of iliopsoas musculotendinopathy with microfiber damage remain a potential. Clinical correlation required.

REFERRING VET

David Lane

INVOICE

57415

DATE

3-23-23



PATIENT

Shiba Pina Bond

SPECIES

Canine

BREED

Shiba Inu

SEX

FS

AGE

6 Years

INTERPRETED BY

Nele Eley, DVM
Dr. med. Vet. DipECVDI

HOSPITAL NAME

Points East West
Veterinary Services

REFERRING VET

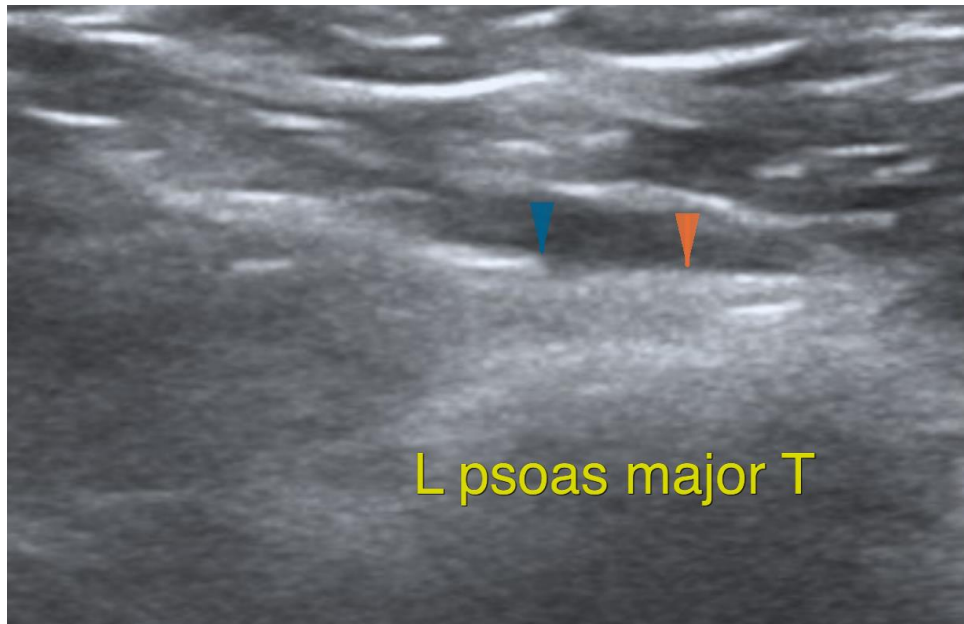
David Lane

INVOICE

57415

DATE

3-23-23



The information and recommendations provided are based on the images presented by the referring veterinarian/sonographer. No evaluation can be communicated regarding pathology that was not visible in the image/video clips provided.

Thank you for this referral. If the clinical or image interpretation does not parallel your findings or if I can be of any further assistance please contact me.

Nele Eley, DVM, Dr. med. vet., DipECVDI
European Specialist in Veterinary Diagnostic Imaging, Cert. Radiology,
Senior lecturer University of Giessen, Germany, Veterinary Faculty, Department of Radiology
Nele.Eley@sonopath.com