

**PATIENT**

Colton Allard

**PRESENTING CLINICAL SIGNS**

Does agility, mild pain on hyperextension of right knee with no palpable effusion/butress/drawer. discomfort palpated on iliopsoas. history of dock diving.

**SPECIES**

Canine

**ULTRASONOGRAPHIC FINDINGS OF THE LEFT & RIGHT ILIOPSOAS**

Mild osseous remodeling is seen at the margins of the femoral head in both coxofemoral joints; however, there is no evidence of coxofemoral joint diffusion or synovial swelling in either of the hind limbs.

**BREED**

Golden Retriever

The right psoas major tendon is ill-defined with unstructured internal echoarchitecture and irregular margination. However, the lesser trochanter of the femur is not clearly seen, and it remains unclear as to whether this is a consequence of pathology or probe alignment.

**SEX**

M

The left psoas major tendon presents within normal limits. The tendon is smoothly delineated with clear margins, uniform internal echoarchitecture, and smooth transitions of the musculotendinous junction and osseous insertion.

**ULTRASONOGRAPHIC DIAGNOSIS****AGE**

9 Years

- Minimal bilateral osseous remodeling of the femoral head - unlikely to be of clinical significance.
- Echoarchitectural changes of the right psoas major tendon: artifact versus iliopsoas tendinopathy.

**INTERPRETED BY**

Nele Eley, DVM  
Dr. med. Vet. DipECVDI

**INTERPRETATION OF THE FINDINGS & FURTHER RECOMMENDATIONS**

It remains open as to whether the changes in the right psoas major tendon reflect actual iliopsoas musculotendinopathy such as chronic repetitive microtrauma or is a result of probe alignment and artifact. Correlate with the clinical examination and remainder of the imaging findings as available. Ultrasonographic recheck and MRI could be considered for further definition depending on the clinical context.

**HOSPITAL NAME**

SVS Imaging

**REFERRING VET**

Dr. Singh

**INVOICE**

51153

**DATE**

3-23-22



**PATIENT**

Colton Allard

**SPECIES**

Canine

**BREED**

Golden Retriever

**SEX**

M

**AGE**

9 Years

**INTERPRETED BY**

Nele Eley, DVM  
Dr. med. Vet. DipECVDI

**HOSPITAL NAME**

SVS Imaging

**REFERRING VET**

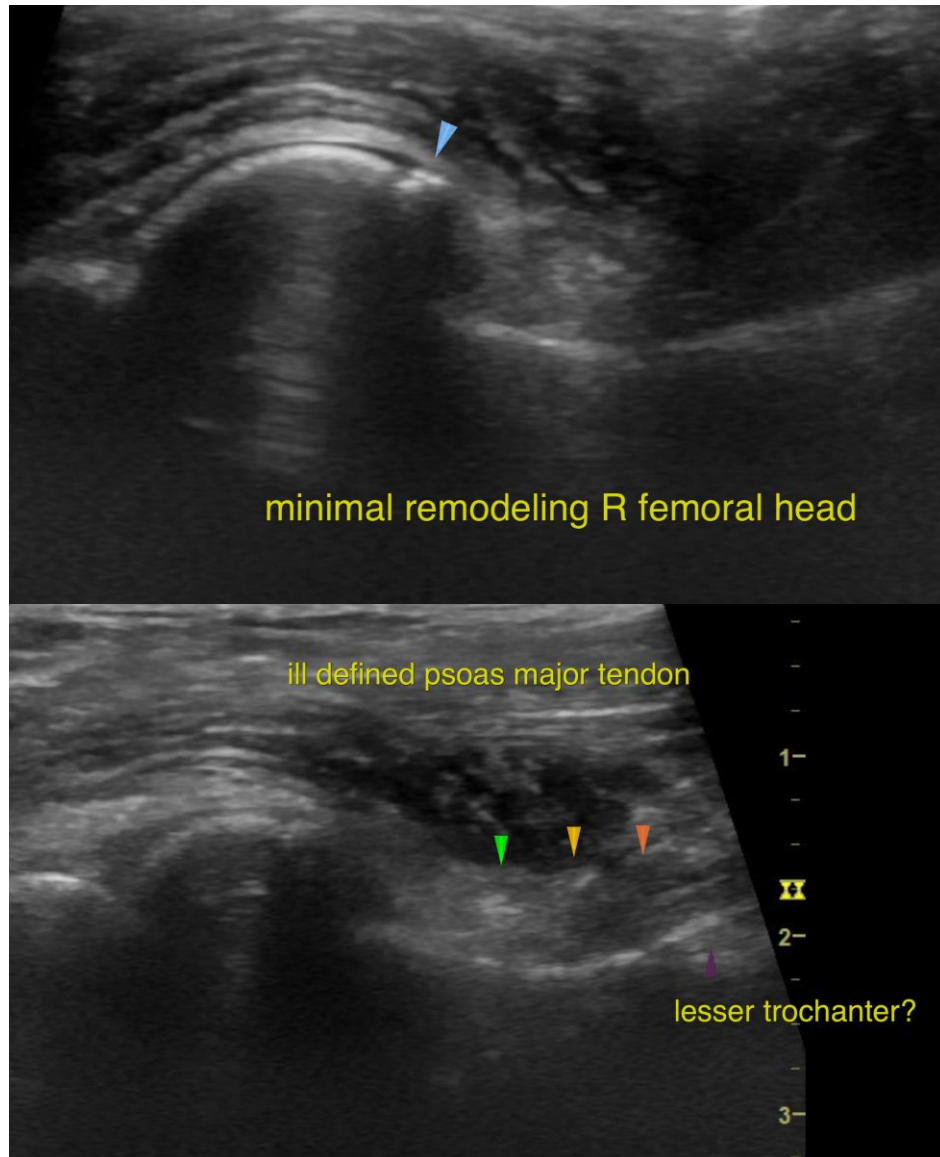
Dr. Singh

**INVOICE**

51153

**DATE**

3-23-22





**PATIENT**

Colton Allard

**SPECIES**

Canine

**BREED**

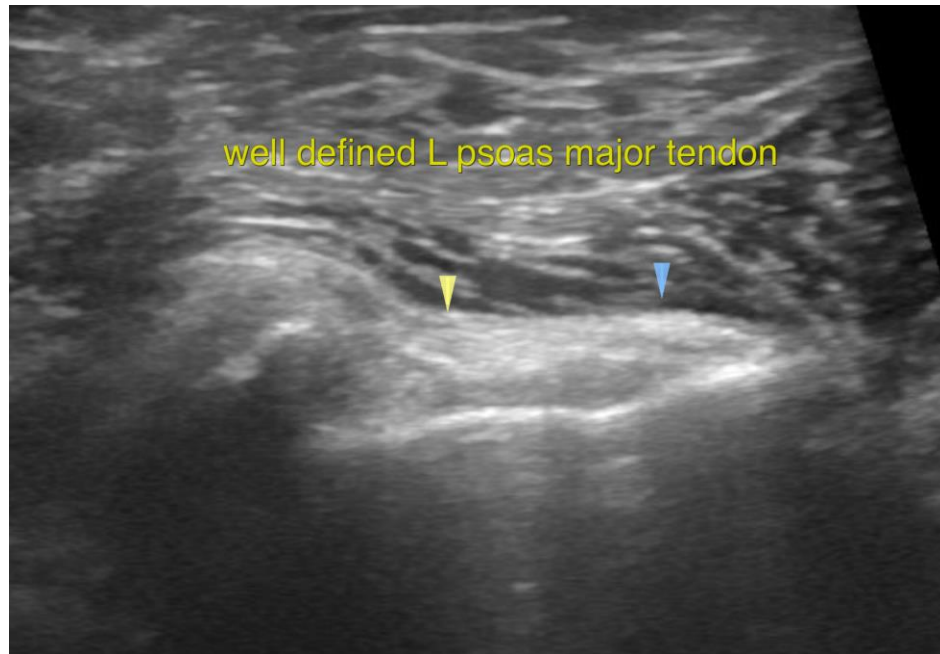
Golden Retriever

**SEX**

M

**AGE**

9 Years



**INTERPRETED BY**

Nele Eley, DVM  
Dr. med. Vet. DipECVDI

**HOSPITAL NAME**

SVS Imaging

**REFERRING VET**

Dr. Singh

**INVOICE**

51153

**DATE**

3-23-22

The information and recommendations provided are based on the images presented by the referring veterinarian/sonographer. No evaluation can be communicated regarding pathology that was not visible in the image/video clips provided.

Thank you for this referral. If the clinical or image interpretation does not parallel your findings or if I can be of any further assistance please contact me.

**Nele Eley**, DVM, Dr. med. vet., DipECVDI  
European Specialist in Veterinary Diagnostic Imaging, Cert. Radiology,  
Senior lecturer University of Giessen, Germany, Veterinary Faculty, Department of Radiology  
Nele.Eley@sonopath.com