



PATIENT PRESENTING CLINICAL SIGNS

Lexie White PERTINENT CLINICAL HISTORY: 7yr, FS, German Shepherd presenting for left calcanean tendon injury LEADING DIFFERENTIAL/DIAGNOSIS: Complete tear vs partial tear vs other

SPECIES ULTRASONOGRAPHIC STUDY OF THE LEFT ACHILLES TENDON

Canine 19 still images and 10 Dicom loops available for review. Contralateral side comparison not available.

BREED ULTRASONOGRAPHIC FINDINGS

German Shepherd The left gastrocnemius tendon presents severe thickening with partial loss of its echoarchitecture and reduced echogenicity over a length of approximately 5 cm starting proximal to the calcaneus. The tuber calcis is not included in the study. However, intact echoarchitecture of the gastrocnemius tendon appears to be present directly proximal to the tuber calcis and the loss of echoarchitecture starts a few millimeters proximal to the tuber calcis. The peripheral peritendineum represented by a thin hyperechoic line appears to be maintained and intact in the most distal part of the left gastrocnemius tendon. At approximately 2.5 cm proximal to the tuber calcis, there is an area of complete loss of echoarchitecture and lost outline of the peritendineum which coincides with the area of the most extensive swelling and lowest echogenicity. Mild fluid accumulation can be seen peripheral to the left gastrocnemius tendon. Gastrocnemius echoarchitecture appears to be maintained level with its musculotendinous junction.

SEX Spayed Female

AGE 7

INTERPRETED BY

Nele Eley, DVM
Dr. med. Vet. DipECVDI

There appears to be moderate distension of the calcaneal bursa which is partially included in the study. The left superficial digital flexor tendon and the composed deep calcaneal tendon appear to be intact except for mild generalized swelling. A dynamic scan is not available.

ULTRASONOGRAPHIC DIAGNOSIS

- Left gastrocnemius tendon injury with regional edema/hemorrhage, calcaneal bursitis, and mild concurrent superficial digital flexor and composed tendon tendinitis.

HOSPITAL NAME

Boren Veterinary
Medical Teaching
Hospital - Oklahoma
State University

INTERPRETATION OF THE FINDINGS & FURTHER RECOMMENDATIONS

The ultrasonographic findings support left calcaneal tendon injury affecting the gastrocnemius tendon. The findings are highly suggestive for complete rupture of the left gastrocnemius tendon. The regional fluid may represent hematoma, edema, or a combination of these.

REFERRING VET

Danielle Dugat

The superficial digital flexor tendon and composed deep calcaneal tendon appear to be continuous and intact. Note the presence of concurrent calcaneal bursitis and tendinitis.

Dynamic scan and comparison with the contralateral side were not available, however, the findings do support an acute traumatic injury rather than chronic degenerative tendinosis as underlying cause of the rupture.

INVOICE

57377

DATE

3-22-23



PATIENT

Lexie White

SPECIES

Canine

BREED

German Shepherd

SEX

Spayed Female

AGE

7

INTERPRETED BY

Nele Eley, DVM
Dr. med. Vet. DipECVDI

HOSPITAL NAME

Boren Veterinary
Medical Teaching
Hospital - Oklahoma
State University

REFERRING VET

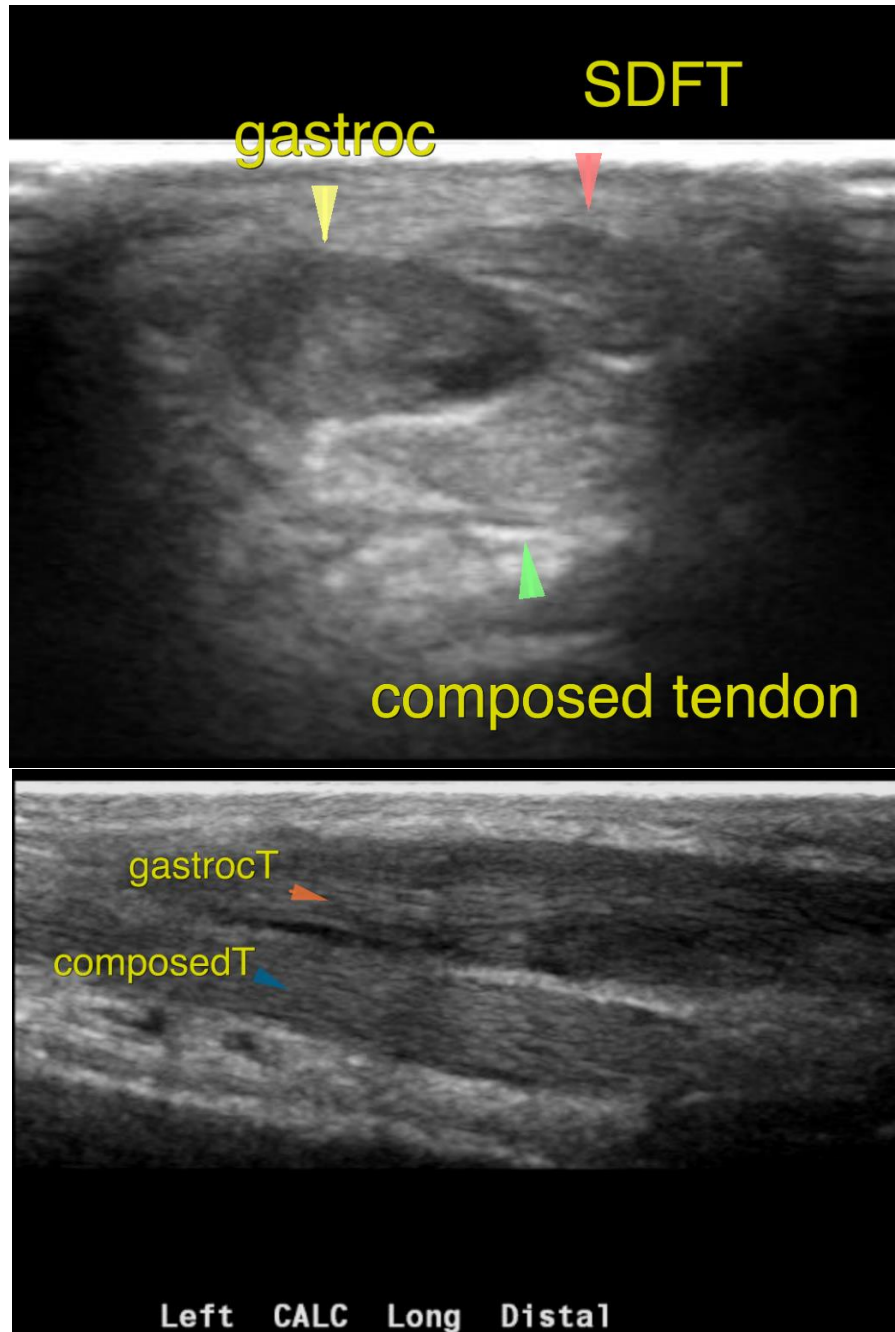
Danielle Dugat

INVOICE

57377

DATE

3-22-23





PATIENT

Lexie White

SPECIES

Canine

BREED

German Shepherd

SEX

Spayed Female

AGE

7

INTERPRETED BY

Nele Eley, DVM
Dr. med. Vet. DipECVDI

HOSPITAL NAME

Boren Veterinary
Medical Teaching
Hospital - Oklahoma
State University

REFERRING VET

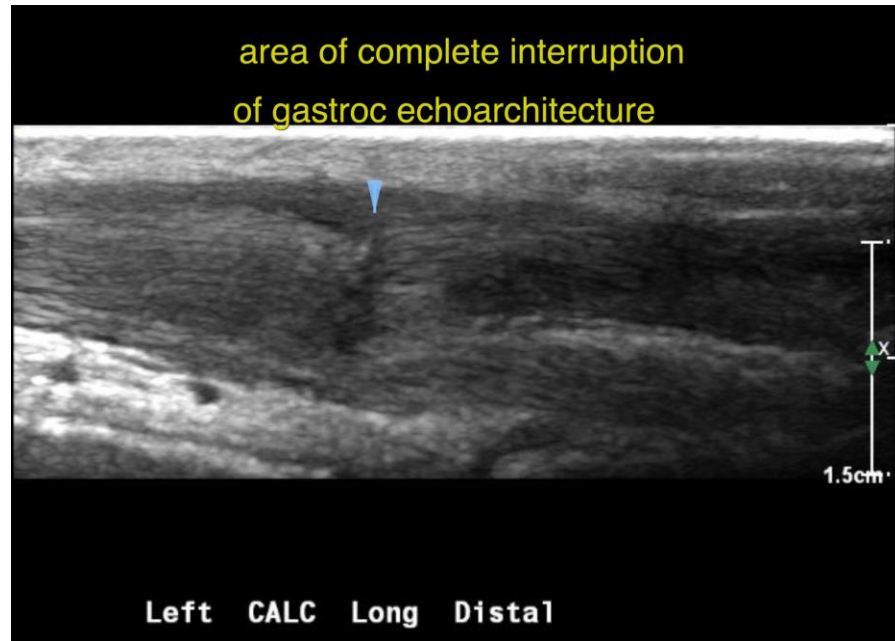
Danielle Dugat

INVOICE

57377

DATE

3-22-23



The information and recommendations provided are based on the images presented by the referring veterinarian/sonographer. No evaluation can be communicated regarding pathology that was not visible in the image/video clips provided.

Thank you for this referral. If the clinical or image interpretation does not parallel your findings or if I can be of any further assistance please contact me.

Nele Eley, DVM, Dr. med. vet., DipECVDI
European Specialist in Veterinary Diagnostic Imaging, Cert. Radiology,
Senior lecturer University of Giessen, Germany, Veterinary Faculty, Department of Radiology
Nele.Eley@sonopath.com