



PATIENT

Jack - O Fernandez

SPECIES

Canine

BREED

Jack Russell Terrier

SEX

Male/Neuter

AGE

14 Years

INTERPRETED BY

Nele Eley, DVM
Dr. med. Vet. DipECVDI

HOSPITAL NAME

Paseos Veterinary
Center

REFERRING VET

Dr. Ferrer, DVM

INVOICE

51110

DATE

3-22-22

PRESENTING CLINICAL SIGNS

Presented for evaluation of coughing. An acute cough started yesterday and the patient has been having increased respiratory sounds. Showed sensitivity on tracheal palpation with coughing and mild possible wheezing and no crackles. No obvious heart murmur was auscultated. Currently on theophylline and when cough ir severe hydrocodone.

RADIOGRAPHIC STUDY OF THE THORAX

Right/left lateral and ventrodorsal views totaling 3 images available for review.

RADIOGRAPHIC FINDINGS

The patient is obese.

The thoracic volume is relatively small.

There is mild caudal cervical and thoracic tracheal collapse upon expiration. No concurrent bronchial collapse is noted.

The lung and bronchial tree present within age related normal limits. Plate-like dystelectasis of the right middle lobe is seen and considered incidental.

The vertebral heart score is 10. Radiographic presentation of the cardiac silhouette and pulmonary vasculature is within normal limits.

Moderate generalized hepatomegaly is seen.

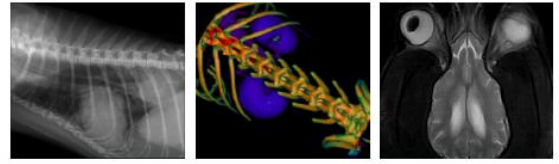
RADIOGRAPHIC DIAGNOSIS

- Suspect dynamic tracheal disease.
- Hepatomegaly.
- Obesity.

INTERPRETATION OF THE FINDINGS & FURTHER RECOMMENDATIONS

The radiographic study suggests presence of dynamic tracheal disease with collapsing trachea upon expiration. The lung and bronchial tree present within age related normal limits. Low grade bronchopneumopathy can never be ruled out entirely as it does not necessarily show radiographically. However, no structural bronchopulmonary changes are noted.

Differential diagnosis for the hepatomegaly includes metabolic/endocrine hepatopathy, diffuse neoplastic, or inflammatory/infectious infiltrates. Correlate with the laboratory values and consider ultrasound with eventual parenchymal sampling if indicated.



PATIENT

Jack - O Fernandez

SPECIES

Canine

BREED

Jack Russell Terrier

SEX

Male/Neuter

AGE

14 Years

INTERPRETED BY

Nele Eley, DVM
Dr. med. Vet. DipECVDI

HOSPITAL NAME

Paseos Veterinary
Center

REFERRING VET

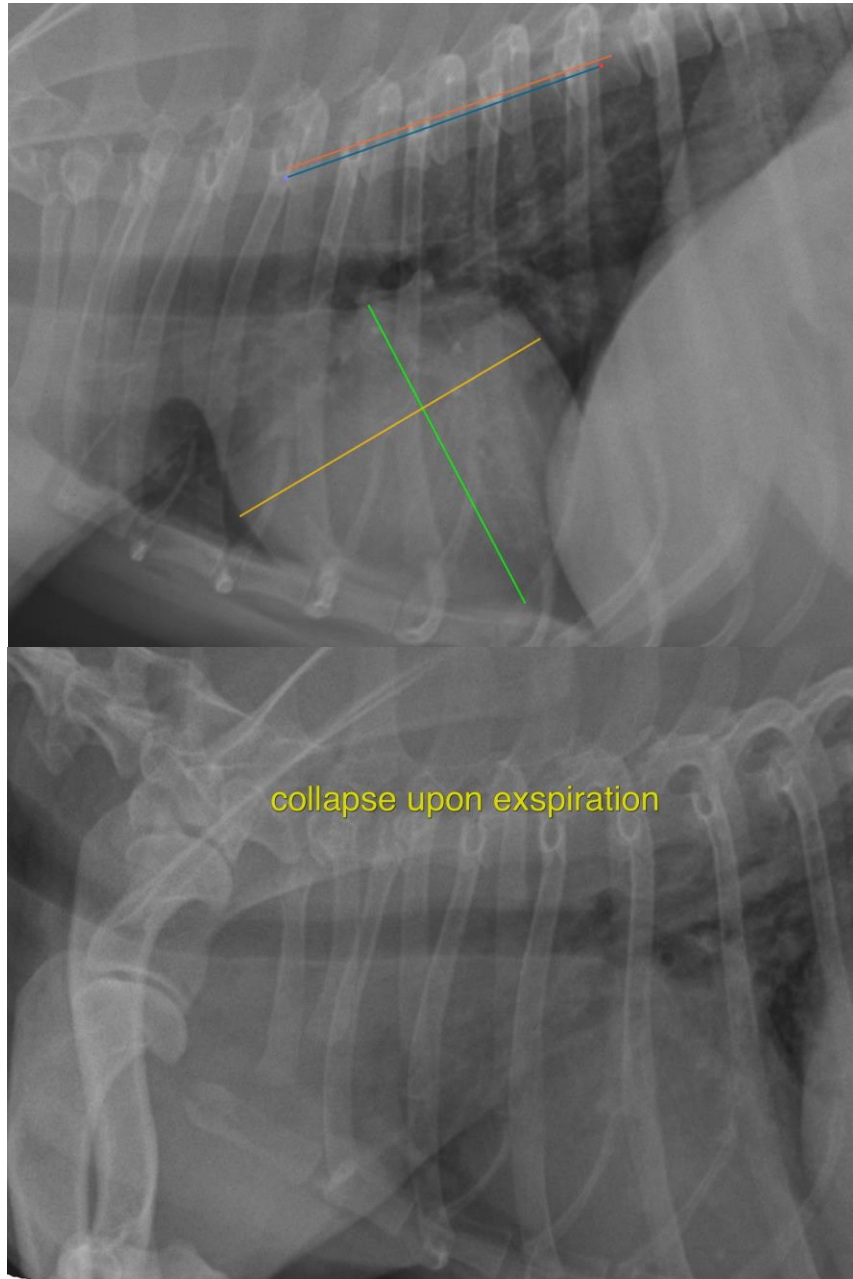
Dr. Ferrer, DVM

INVOICE

51110

DATE

3-22-22





PATIENT

Jack - O Fernandez

The information and recommendations provided are based on the images presented by the referring veterinarian/sonographer. No evaluation can be communicated regarding pathology that was not visible in the image/video clips provided.

Thank you for this referral. If the clinical or image interpretation does not parallel your findings or if I can be of any further assistance please contact me.

SPECIES

Canine

Nele Eley, DVM, Dr. med. vet., DipECVDI
European Specialist in Veterinary Diagnostic Imaging, Cert. Radiology,
Senior lecturer University of Giessen, Germany, Veterinary Faculty, Department of Radiology
Nele.Eley@sonopath.com

BREED

Jack Russell Terrier

SEX

Male/Neuter

AGE

14 Years

INTERPRETED BY

Nele Eley, DVM
Dr. med. Vet. DipECVDI

HOSPITAL NAME

Paseos Veterinary
Center

REFERRING VET

Dr. Ferrer, DVM

INVOICE

51110

DATE

3-22-22