



PATIENT PRESENTING CLINICAL SIGNS

Mya Young Had TTA on the right knee July 2022. Started limping on the left stifle in Jan this year.
 Abnormal PE/Chem/CBC/UA Results: Has slight Cranial drawer sign in flexion only in the left knee along with a slight CTT. prominent Med buttress sign. Xrays July 2022` 1) Bilateral stifle effusion and arthritis, worse on the right, likely compatible with an intra-articular injury such as a partial/complete cruciate rupture and/or meniscal damage. 2. Bilateral moderate coxofemoral arthritis. While this could be contributing to clinical signs, it is unlikely that this finding is the primary cause of the clinical signs. 3. Unremarkable right and left tarsus.

SPECIES

Canine

BREED

Lab

ULTRASONOGRAPHIC FINDINGS

Left Stifle

A mild to moderate amount of osteophytes are seen in the periarticular margins. Moderate effusion is present within the left stifle joint.

SEX

FS

The cranial cruciate ligament presents continuous but is thick with nonuniform internal echoarchitecture and ill-defined margins. The medial meniscus is in situ.

AGE

6 Years, 11 Months

The top of the tibia is hook shaped which creates the impression of an isolated bone piece which actually is attached to the remainder of the tibia and a normal anatomic variant.

Medial collateral ligament thickening is seen.

INTERPRETED BY

Nele Eley, DVM
 Dr. med. Vet. DipECVDI

ULTRASONOGRAPHIC DIAGNOSIS

- Mild to moderate left stifle osteoarthritis with cranial cruciate ligament pathology and no evidence of meniscal injury.

INTERPRETATION OF THE FINDINGS & FURTHER RECOMMENDATIONS

The ultrasonographic findings are compatible with partial rupture of the left cranial cruciate ligament. Mild to moderate concurrent osteoarthritis of the left stifle joint is noted and surgical intervention should be considered in order to address the ongoing failure of the biomechanical function of the cruciate ligament.

HOSPITAL NAME

Westview Veterinary Hospital

REFERRING VET

Dr. Brian Barnes

INVOICE

57358

DATE

3-21-23



PATIENT

Mya Young

SPECIES

Canine

BREED

Lab

SEX

FS

AGE

6 Years, 11 Months

INTERPRETED BY

Nele Eley, DVM
Dr. med. Vet. DipECVDI

HOSPITAL NAME

Westview Veterinary
Hospital

REFERRING VET

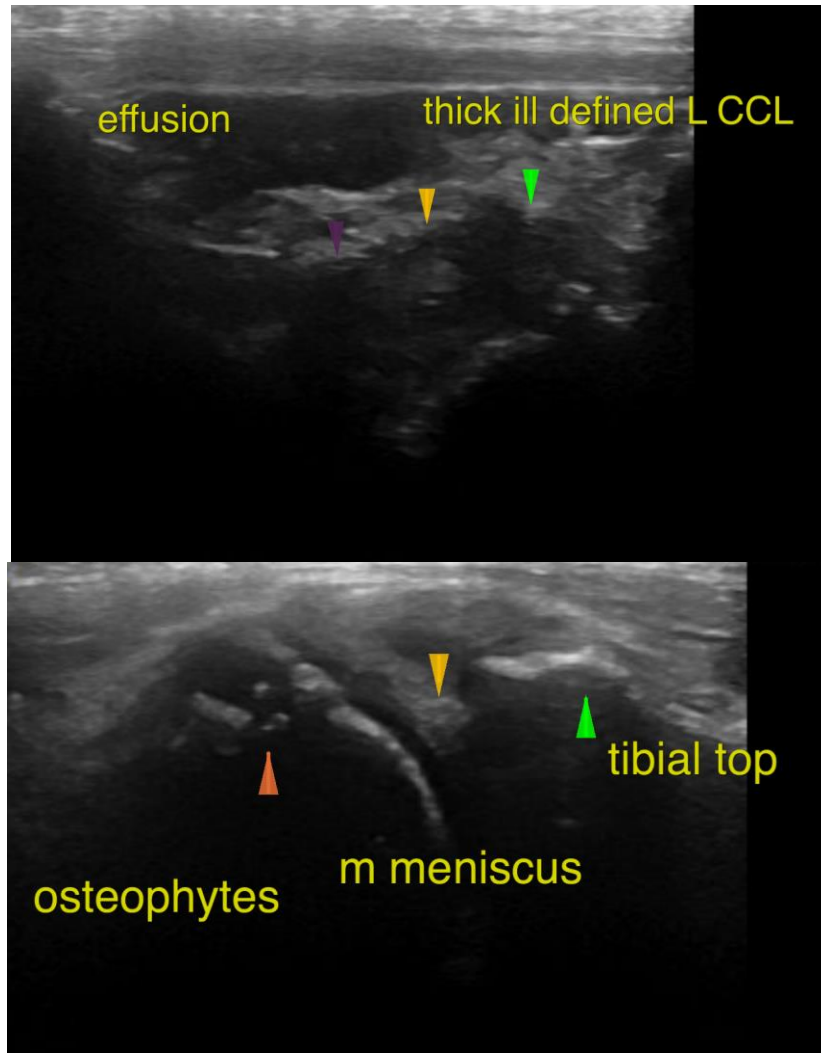
Dr. Brian Barnes

INVOICE

57358

DATE

3-21-23



The information and recommendations provided are based on the images presented by the referring veterinarian/sonographer. No evaluation can be communicated regarding pathology that was not visible in the image/video clips provided.

Thank you for this referral. If the clinical or image interpretation does not parallel your findings or if I can be of any further assistance please contact me.

Nele Eley, DVM, Dr. med. vet., DipECVDI
European Specialist in Veterinary Diagnostic Imaging, Cert. Radiology,
Senior lecturer University of Giessen, Germany, Veterinary Faculty, Department of Radiology
Nele.Eley@sonopath.com