



**PATIENT**

Mouse Hankinson

**PRESENTING CLINICAL SIGNS**

right maxillary mast cell tumor

**COMPUTED TOMOGRAPHIC STUDY OF THE HEAD, NECK, THORAX, ABDOMEN, & SPINE**

**SPECIES**

Feline

Post contrast studies available for review. Motion artifact noted within the thorax and abdomen resulting in multiple high density streaks.

**COMPUTED TOMOGRAPHIC FINDINGS**

**BREED**

DSH

Patient has a history of right maxillary mast cell tumor.

**Head & Neck**

**SEX**

Female

An irregular shaped ill-defined ulcerating mass is seen in the right sides of the face. The mass is directly adjacent to the right maxilla and zygomatic arch and measures 30mm in length, 18mm in width, and 24mm in height respectively. Mineralization, cavitation, and nonuniform contrast enhancement are seen within the mass. There is no evidence of involvement of the underlying bones.

**AGE**

14 Years

The right submandibular, parotid, and medial retropharyngeal present moderate symmetric enlargement.

**INTERPRETED BY**

Nele Eley, DVM  
Dr. med. Vet. DipECVDI

Both tympanic bullae are filled with a moderate amount of fluid attenuating material. Mild thickening of their osseous lining is seen. The external auditory meatuses present within normal limits.

Both lobes of the thyroid gland are seen and present within normal limits.

The bilateral cervical lymph nodes are mildly enlarged.

**HOSPITAL NAME**

Animal Surgical  
Center

**Thorax**

The bony and surrounding soft tissue structures are within normal limits.

**REFERRING VET**

Peace Love Pets

The sternal, cranial mediastinal and tracheobronchial lymph nodes are small elongated with a normal short-to-long-axis-ratio is < 0.5, the attenuation and contrast enhancement pattern are uniform and considered within normal limits.

The cardiovascular structures including the pulmonary vasculature are within normal limits.

**INVOICE**

57407

A mild generalized bronchial lung pattern and right cranial and right middle lobe atelectasis are noted. No evidence of interstitial pulmonary nodules or masses are seen.

Small incidental gas pockets are seen within the esophageal lumen, there is no evidence of abnormal dilation.

**DATE**

3-21-23

**Abdomen**

The serosal fat presents normal attenuation behavior. There is no evidence of peritoneal effusion



**PATIENT** or peritonitis.

**Mouse Hankinson** Both kidneys present cortical renal infarcts rendering the renal surface slightly irregular. Mineral attenuating foci are seen within the renal diverticuli.

**SPECIES** The adrenal glands are within normal limits for size, shape and organ architecture.

**Feline** Both liver and spleen present with normal shape, even surface, uniformly attenuating parenchyma and homogeneous contrast enhancement, unremarkable.

**BREED** The pancreas is evenly contoured, the pancreatic parenchyma is homogeneous and presents uniform contrast enhancement.

**DSH** The position, delineation, wall and content of the gastrointestinal tract are considered within normal limits throughout.

**SEX** Multiple spondyloses are seen between T12 and L4.

**Female** Moderate degenerative lumbosacral stenosis is noted.

**AGE** **COMPUTED TOMOGRAPHIC DIAGNOSIS**

- 14 Years**
- Large ulcerative mineralizing soft tissue mass in the right side of the face with aggressive biological behavior compatible with the history of mast cell tumor, no evidence of underlying bone involvement.
  - Right retropharyngeal, submandibular, parotid, and bilateral cervical lymphadenomegaly.
  - Bilateral otitis media.
  - Bronchial lung pattern with lobar atelectasis.
  - No evidence of pulmonary metastases.
  - Suspect chronic bilateral nephropathy.
  - Multiple spondyloses.
  - Degenerative lumbosacral stenosis.

**INTERPRETED BY**

Nele Eley, DVM  
Dr. med. Vet. DipECVDI

**HOSPITAL NAME**

Animal Surgical  
Center

**REFERRING VET**

Peace Love Pets

**INVOICE**

57407

**DATE**

3-21-23

**INTERPRETATION OF THE FINDINGS & FURTHER RECOMMENDATIONS**

The CT study reveals a soft tissue mass meeting neoplastic criteria in the right side of the face. The findings are compatible with the history of mast cell tumor. Ulceration and mineralization of the mass are noted. There is no evidence of aggressive osteolytic changes. However, the mass is directly adjacent to the underlying zygomatic arch and maxilla.

The lymph node changes are suggestive for metastatic disease. Reactive hyperplasia cannot be ruled out entirely. Fine needle aspiration is recommended for further definition.

No evidence of pulmonary metastases was found.

The pulmonary changes suggest potential for chronic allergic lower airway disease with lobar atelectasis secondary to mucus plugging. Infectious bronchitis is a possible differential diagnosis. The findings are not compatible with neoplasia/metastases.



**PATIENT**

Mouse Hankinson

**SPECIES**

Feline

**BREED**

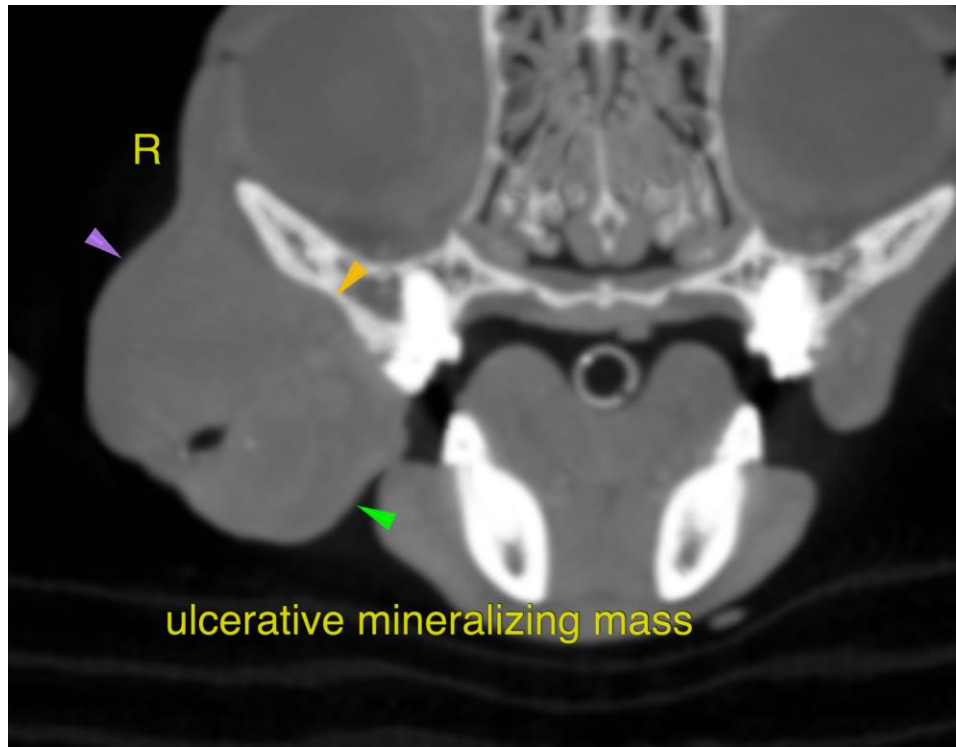
DSH

**SEX**

Female

**AGE**

14 Years



**INTERPRETED BY**

Nele Eley, DVM  
Dr. med. Vet. DipECVDI

The information and recommendations provided are based on the images presented by the referring veterinarian/sonographer. No evaluation can be communicated regarding pathology that was not visible in the image/video clips provided.

**HOSPITAL NAME**

Animal Surgical  
Center

Thank you for this referral. If the clinical or image interpretation does not parallel your findings or if I can be of any further assistance please contact me.

**Nele Eley**, DVM, Dr. med. vet., DipECVDI  
European Specialist in Veterinary Diagnostic Imaging, Cert. Radiology,  
Senior lecturer University of Giessen, Germany, Veterinary Faculty, Department of Radiology  
Nele.Eley@sonopath.com

**REFERRING VET**

Peace Love Pets

**INVOICE**

57407

**DATE**

3-21-23