**DATE PRESENTING CLINICAL SIGNS**

3-21-22 Changes in eating behavior; eating slower than usual. Fractured left mandibular canine; previous adenosquamous carcinoma mass under tongue (partially resected 10/2020) possibly SCC.

PATIENT RADIOGRAPHIC STUDY OF THE THORAX

Sullywag Henson Right/left lateral and ventrodorsal views totaling 3 images available for review.

SPECIES RADIOGRAPHIC FINDINGS

Canine Multiple mild to severe spondyloses are seen within the mid and caudal thoracic spine.
There is mild bilateral elbow osteoarthritis.

BREED The extrathoracic soft tissues present homogeneous without abnormalities.

Corgi The heart is of normal size and shape and there is no evidence of cardiac chamber or vascular enlargement. The pulmonary vasculature is within normal limits.

SEX The cranial mediastinum presents the expected soft tissue opacity. The mediastinal width is less than twice the width of the vertebral column at the same level.

Female Spayed

AGE The trachea is normal in diameter and presents the anticipated course. The luminal outline of the trachea is smooth.

July 20, 2011 (11) A 3.5 x 2.0 cm sized soft tissue opaque mass is seen in the left lung. The mass presents border effacement with the left dorsal contour of the cardiac silhouette and appears to be situated within the caudal subsegment of the left cranial lung lobe. However, left caudal lung lobe origin cannot be ruled out entirely. A second nodule appears to be present in the caudal and dorsal aspect of the left caudal lung lobe.

INTERPRETED BY

Nele Ondreka, DVM
Dr. med. vet.,
DipECVDI The diaphragm is well delineated with even surface and the expected mild cranial bulging of the diaphragmatic cupola.

RADIOGRAPHIC DIAGNOSIS**HOSPITAL NAME**

Claws N Paws
Animal Hospital

- Nodular interstitial lung pattern.
- Spondyloses.
- Bilateral elbow osteoarthritis.

INTERPRETATION OF FINDINGS & FURTHER RECOMMENDATIONS

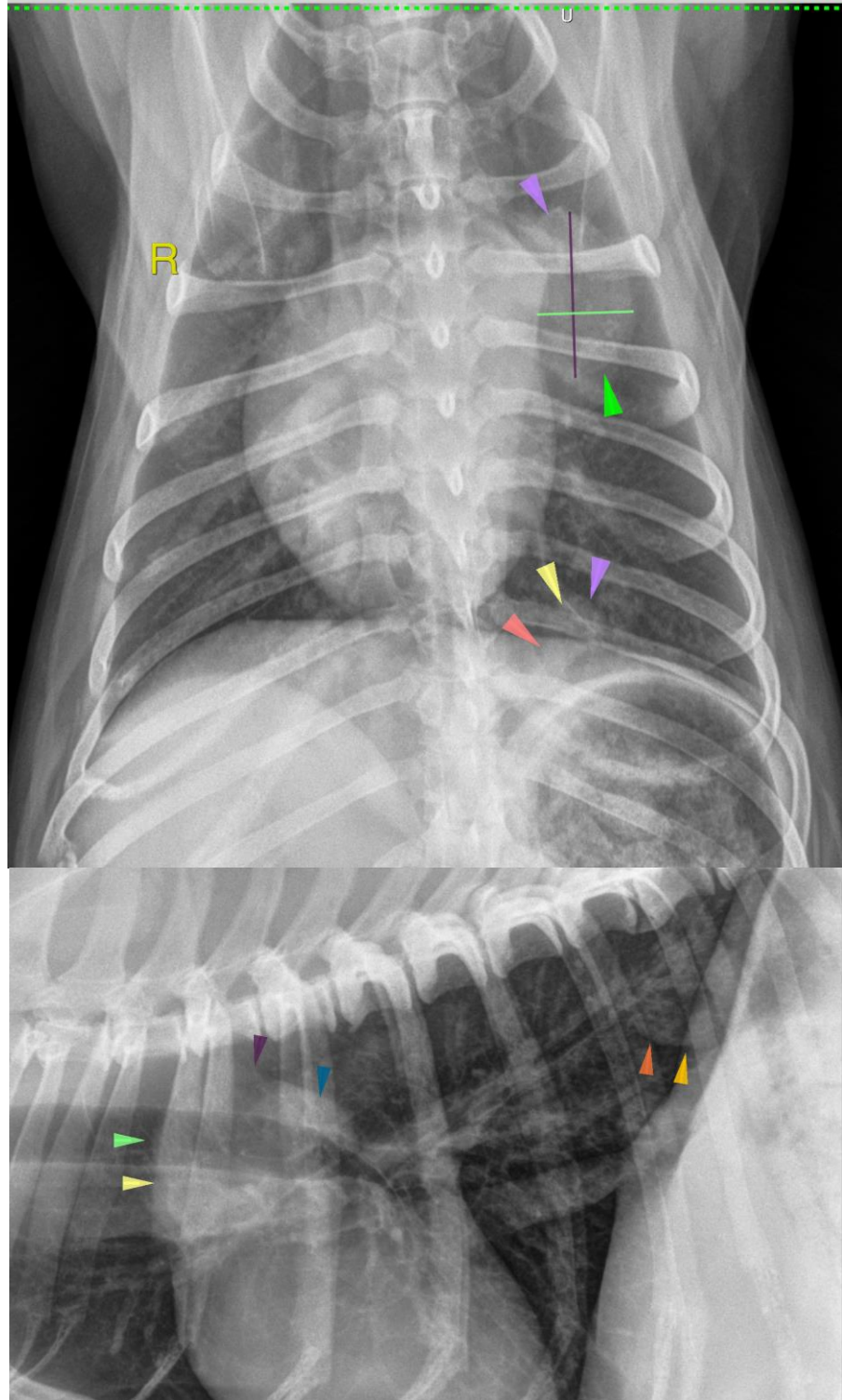
REFERRING VET The radiographic study suggests presence of two soft tissue nodules within the left lung. A larger nodule / mass appears to be situated in the caudal subsegment of the left cranial lung lobe. A smaller nodule is seen in the caudodorsal aspect of the left caudal lung lobe. Differential diagnosis includes secondary neoplasia of the lung including round cell neoplasia, sarcoma, metastatic disease, and less likely primary neoplasia of the lung such as bronchial carcinoma. Pulmonary abscesses or granulomas cannot be ruled out entirely but are thought by far less likely, especially considering the clinical history of this patient. Unfortunately, both nodules are not accessible for

Singh

INVOICE

51067

ultrasound guided fine needle aspiration and CT with CT guided biopsies would be required for further definition.



The information and recommendations provided are based on the images presented by the referring veterinarian/sonographer. No evaluation can be communicated regarding pathology that was not visible in the image/video clips provided.

Thank you for this referral. If the clinical or image interpretation does not parallel your findings or if I can be of any further assistance please contact me.

Nele Eley (Ondreka), DVM, Dr. med. vet., DipECVDI
European Specialist in Veterinary Diagnostic Imaging, Cert. Radiology,
Senior lecturer University of Giessen/Germany, Veterinary Faculty, Department of Radiology.
Nele.Eley@sonopath.com