



PATIENT PRESENTING CLINICAL SIGNS

Otto Riley Sent in house rads in previous requisition. These are rads from emergency clinic (couldn't put them all in one submission)

SPECIES RADIOGRAPHIC STUDY OF THE THORAX

Ca Multiple studies dated 1-31-22, 2-17-22, 2-21-22, and 3-21-22 of the thorax including right/left lateral and orthogonal views available totaling 15 images.

BREED RADIOGRAPHIC FINDINGS

Golden Images dated 2-21 provided in jpeg format by another institution show the most extensive changes in terms of pneumonia. An extensive ventral and cranial alveolar infiltrate is seen accentuating the right cranial, middle, and caudal lobes. The remainder of the lung presents a mild bronchointerstitial lung pattern.

SEX

MN The following and recent study all show progressive clearance of the alveolar infiltrate even though a peripheral soft tissue opaque infiltrate still appears to be present within the right cranial and right middle lung lobes. Most of the right lung, however, appears to have cleared. A mild residual increase in interstitial background opacity is seen within the right and left cranial lung lobes.

AGE

6 The cardiac silhouette is upright and thin. Pulmonary vasculature is thin.

INTERPRETED BY

Nele Eley, DVM
Dr. med. Vet. DipECVDI

Course and width of the trachea are considered within normal limits.

There is no evidence of pleural effusion or mediastinal lymphadenomegaly.

Gastric aerophagia is noted.

HOSPITAL NAME

Torch Lake
Veterinary Clinic

RADIOGRAPHIC DIAGNOSIS

- Progressive clearing of a cranioventral alveolar pulmonary infiltrate with mild residual alveolar and interstitial lung pattern within right and left cranial and right middle lung lobes.
- Mild microcardia and underperfusion of the lung - compatible with hypovolemia.

REFERRING VET

A Waffle

INTERPRETATION OF THE FINDINGS & FURTHER RECOMMENDATIONS

A small amount of residual peripheral alveolar infiltrate appears to be present in the recent study. Other than that, most of the alveolar infiltrate has cleared from the cranioventral and right lung. Mild increase in interstitial background opacity is seen and may be compatible with inflammatory infiltrate as well as edema and dystelectasis. It has to be noted that radiographic signs always lag behind the clinical course of the disease. However, continuation of the antimicrobial treatment until all visible pulmonary infiltrate has cleared should be considered.

INVOICE

51068

DATE

3-21-22



PATIENT

Otto Riley

SPECIES

Ca

BREED

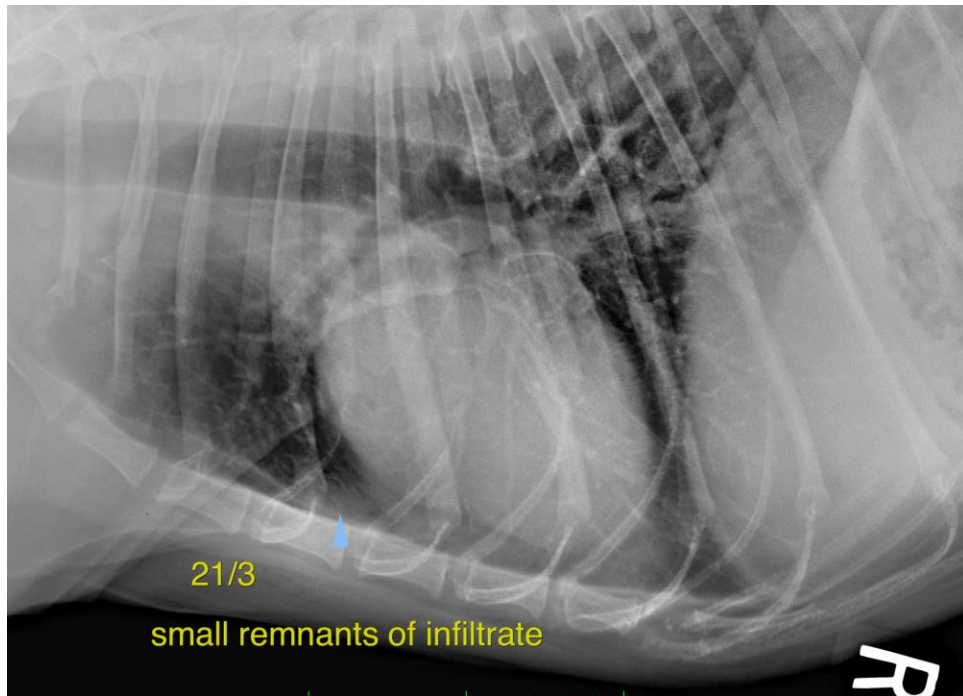
Golden

SEX

MN

AGE

6



INTERPRETED BY

Nele Eley, DVM
Dr. med. Vet. DipECVDI

The information and recommendations provided are based on the images presented by the referring veterinarian/sonographer. No evaluation can be communicated regarding pathology that was not visible in the image/video clips provided.

HOSPITAL NAME

Torch Lake
Veterinary Clinic

Thank you for this referral. If the clinical or image interpretation does not parallel your findings or if I can be of any further assistance please contact me.

Nele Eley, DVM, Dr. med. vet., DipECVDI
European Specialist in Veterinary Diagnostic Imaging, Cert. Radiology,
Senior lecturer University of Giessen, Germany, Veterinary Faculty, Department of Radiology
Nele.Eley@sonopath.com

REFERRING VET

A Waffle

INVOICE

51068

DATE

3-21-22