



PATIENT

Gracie Tate

PRESENTING CLINICAL SIGNS

Grade III/VI heart murmur, chronic cough for several years. Mildly progressed a few months ago. Mild exercise intolerance.

SPECIES

Canine

RADIOGRAPHIC STUDY OF THE THORAX

Right/left lateral and ventrodorsal views totaling 3 images available for review.

BREED

Chihuahua

RADIOGRAPHIC FINDINGS

The thoracic volume appears to be rather low.

SEX

Spayed Female

Moderate enlargement of the cardiac silhouette is noted with elevation of the trachea, left atrial tenting, and a vertebral heart score of 12.4. No evidence of cardiogenic pulmonary edema is seen at this point. A double opacity sign and bronchial splitting with lift of the left mainstem bronchus are seen on the orthogonal views.

Collapsing of the trachea is seen in the caudocervical area of the left lateral view.

AGE

9 Years, 11 Months

The stomach is postprandial and presents mild aerophagia.

INTERPRETED BY

Nele Eley, DVM
Dr. med. Vet. DipECVDI

RADIOGRAPHIC DIAGNOSIS

- Moderate left sided cardiomegaly with left atrial enlargement and bronchial splitting.
- No evidence of congestive heart failure/cardiogenic pulmonary edema.
- Mild dynamic tracheal collapse.
- Aerophagia.

HOSPITAL NAME

All Creatures Animal
Hospital of South Hill,
Inc.

INTERPRETATION OF THE FINDINGS & FURTHER RECOMMENDATIONS

The radiographic findings are compatible with the history of chronic mitral valve regurgitation. Degeneration of the mitral valve is considered most likely. The degree of overall cardiac and left atrial enlargement is considered moderate. At this time, there is no cardiogenic pulmonary edema seen. Note the presence of dynamic tracheal disease.

A cardiac echo could be performed in order to allow a detailed staging of the presumed mitral valve disease and to adjust the medical treatment accordingly.

REFERRING VET

Dr. Amanda Hart

INVOICE

51076

DATE

3-21-22



PATIENT

Gracie Tate

SPECIES

Canine

BREED

Chihuahua

SEX

Spayed Female

AGE

9 Years, 11 Months

INTERPRETED BY

Nele Eley, DVM
Dr. med. Vet. DipECVDI

HOSPITAL NAME

All Creatures Animal
Hospital of South Hill,
Inc.

REFERRING VET

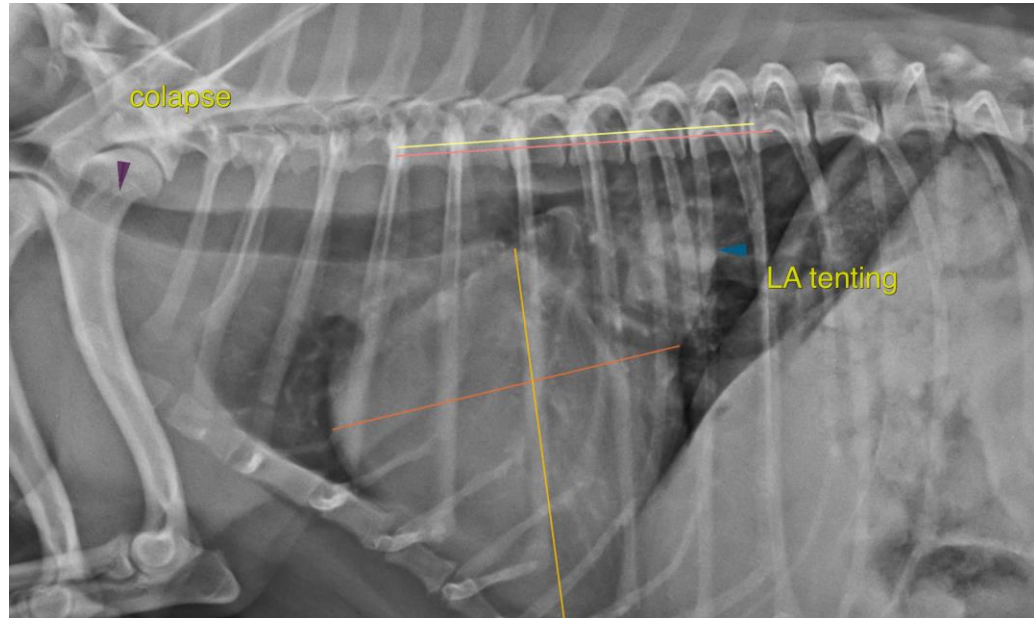
Dr. Amanda Hart

INVOICE

51076

DATE

3-21-22



The information and recommendations provided are based on the images presented by the referring veterinarian/sonographer. No evaluation can be communicated regarding pathology that was not visible in the image/video clips provided.

Thank you for this referral. If the clinical or image interpretation does not parallel your findings or if I can be of any further assistance please contact me.

Nele Eley, DVM, Dr. med. vet., DipECVDI
European Specialist in Veterinary Diagnostic Imaging, Cert. Radiology,
Senior lecturer University of Giessen, Germany, Veterinary Faculty, Department of Radiology
Nele.Eley@sonopath.com