



PATIENT

Cheeky Caldwell

PRESENTING CLINICAL SIGNS

bloody diarrhea for few days
 Abnormal PE/Chem/CBC/UA Results: significant elevation in ALP and cPLI mild elevation of WBC

SPECIES

Canine

RADIOGRAPHIC STUDY OF THE ABDOMEN

Right/left lateral and ventrodorsal views of the abdomen totaling 3 images available for review.

BREED

Shih Tzu

RADIOGRAPHIC FINDINGS

There is the impression of a soft tissue nodule within the caudodorsal lung on the right lateral view of the abdomen which is not repeated in the left lateral or orthogonal views and may well represent summation artifact.

SEX

Female Spayed

Abdomen

The patient is obese.

AGE

14 Years

The abdominal serosal detail appears to be maintained.

Moderate generalized enlargement of the liver with slightly rounded lobar margins is noted. There is mild caudodorsal deviation of the gastric pylorus.

INTERPRETED BY

Nele Eley, DVM
 Dr. med. Vet. DipECVDI

The stomach is postprandial.

The small intestinal loops are turgid in appearance with predominance of a gas pattern. No evidence abnormal dilation, plication, or radiopaque foreign material is seen.

HOSPITAL NAME

St. Catherine's Animal
 Hospital

RADIOGRAPHIC DIAGNOSIS

- Gastrointestinal maldigestion pattern.
- Moderate hepatomegaly.
- Questionable soft tissue nodule in the caudodorsal lung.

REFERRING VET

Dr. Boctor

INTERPRETATION OF THE FINDINGS & FURTHER RECOMMENDATIONS

No radiographic evidence of peritonitis was seen yet there is a small intestinal maldigestion pattern which is an unspecific finding but can be seen with pancreatitis and other gastroenteropathy.

INVOICE

51072

Differential diagnosis for the hepatomegaly includes metabolic/endocrine hepatopathy. Hepatitis and diffuse neoplastic infiltrate cannot be ruled out. Correlate with the laboratory values and consider abdominal ultrasound for further definition if indicated.

DATE

3-21-22

Three view thoracic radiographs could be considered in order to rule out presence of pulmonary interstitial nodules.



PATIENT

Cheeky Caldwell

SPECIES

Canine

BREED

Shih Tzu

SEX

Female Spayed

AGE

14 Years

INTERPRETED BY

Nele Eley, DVM
Dr. med. Vet. DipECVDI

HOSPITAL NAME

St. Catherine's Animal
Hospital

REFERRING VET

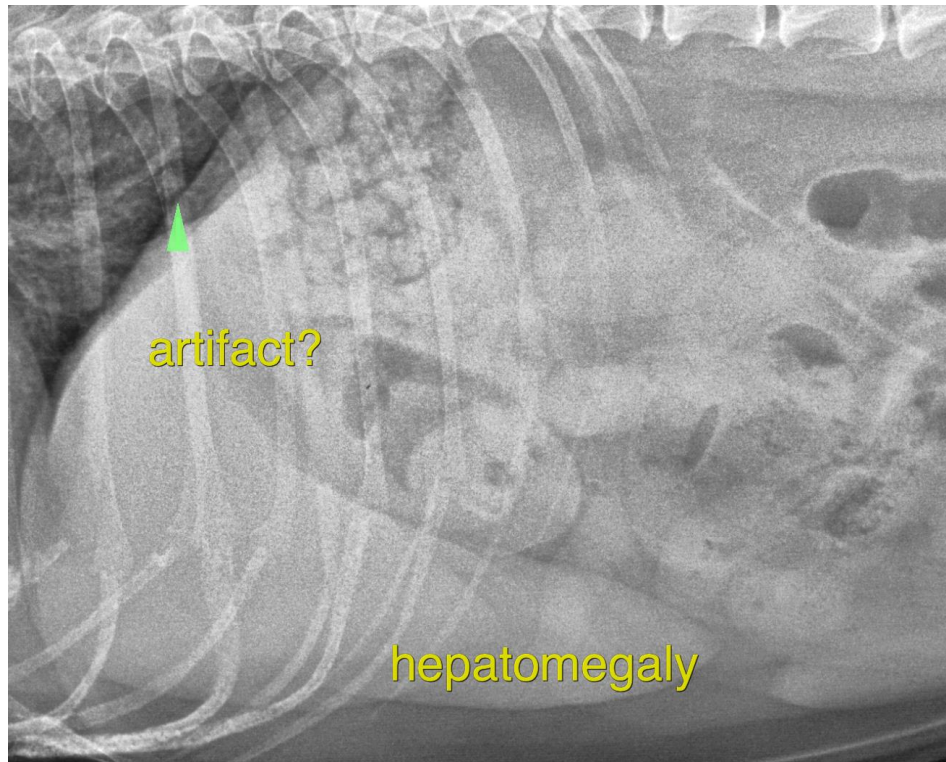
Dr. Boctor

INVOICE

51072

DATE

3-21-22



The information and recommendations provided are based on the images presented by the referring veterinarian/sonographer. No evaluation can be communicated regarding pathology that was not visible in the image/video clips provided.

Thank you for this referral. If the clinical or image interpretation does not parallel your findings or if I can be of any further assistance please contact me.

Nele Eley, DVM, Dr. med. vet., DipECVDI
European Specialist in Veterinary Diagnostic Imaging, Cert. Radiology,
Senior lecturer University of Giessen, Germany, Veterinary Faculty, Department of Radiology
Nele.Eley@sonopath.com