



**PATIENT**

Beau Wesley

**PRESENTING CLINICAL SIGNS**

Coughing at Christmas, then stopped until February, and started coughing again in March with an increase in frequent coughing fits at night and early morning.  
Abnormal PE/Chem/CBC/UA Results: Grade 1 heart murmur

**SPECIES**

Canine

**RADIOGRAPHIC STUDY OF THE THORAX**

Right/left lateral and ventrodorsal views totaling 4 images available for review.

**BREED**

Poodle

**RADIOGRAPHIC FINDINGS**

Early mid thoracic spondylosis deformans is noted.

**SEX**

Male Neutered

The degree of pulmonary inflation is deep. A mild generalized bronchointerstitial lung pattern is noted and evenly distributed throughout the lung. There is no evidence of alveolar infiltrates, pulmonary nodules, or masses.

No evidence of mediastinal lymphadenomegaly is seen.

**AGE**

7 Years

Course and width of the trachea are considered within normal limits.

The radiographic presentation of the cardiac silhouette is considered within normal limits. The vertebral heart score is 10.

**INTERPRETED BY**

Nele Eley, DVM  
Dr. med. Vet. DipECVDI

Mild esophageal aerophagia is seen and considered incidental.

There is mild gastric aerophagia.

Cylindrical mineral opaque structures are seen within the pyloric antrum (bones).

**HOSPITAL NAME**

Truscott Animal  
Hospital

**RADIOGRAPHIC DIAGNOSIS**

- Normal age related thorax.
- Aerophagia.
- Ingestion of bones.

**REFERRING VET**

Mina Abdelsayed

**INTERPRETATION OF THE FINDINGS & FURTHER RECOMMENDATIONS**

The radiographic presentation of the lung and bronchial tree is considered within age related normal limits. Emerging or low grade pneumonia can never be ruled out entirely and may be occult radiographically. However, no clear signs of pulmonary or lower airway disease are seen radiographically. T

**INVOICE**

51075

he radiographic presentation of the cardiac silhouette is within normal limits.

**DATE**

3-21-22

Further evaluation of the upper and lower airways by means of endoscopy including airway sampling could be considered depending on the clinical context or correlation.



**PATIENT**

Beau Wesley

**SPECIES**

Canine

**BREED**

Poodle

**SEX**

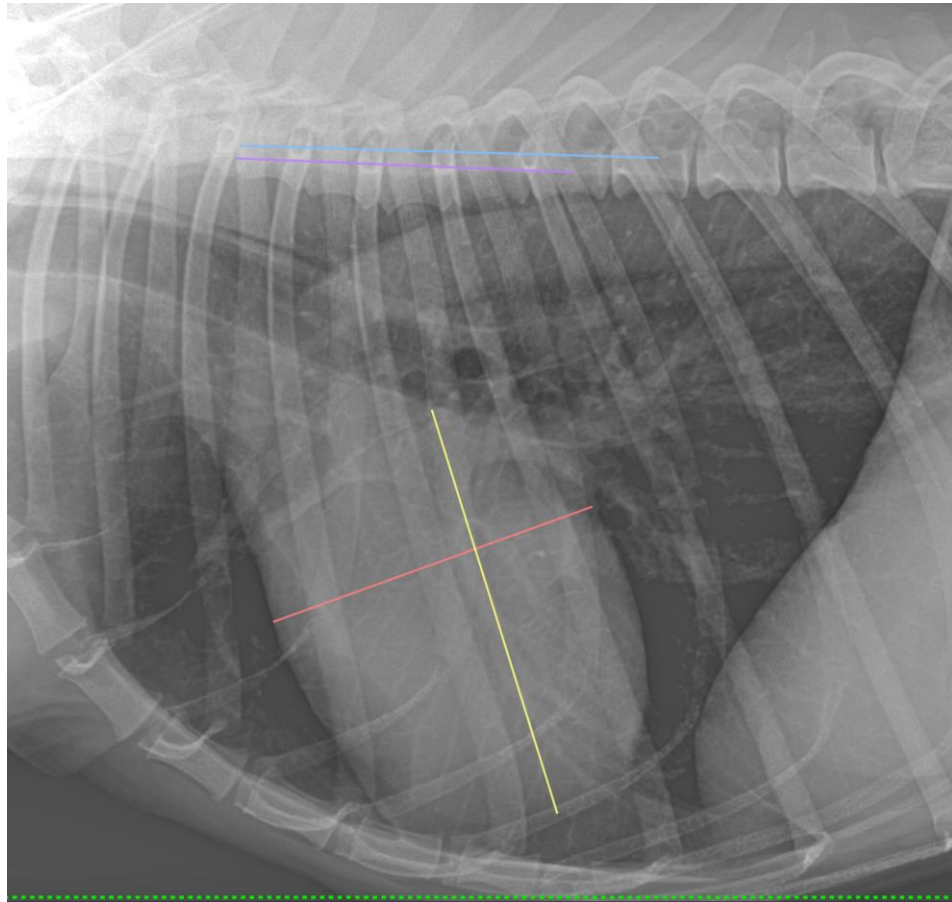
Male Neutered

**AGE**

7 Years

**INTERPRETED BY**

Nele Eley, DVM  
Dr. med. Vet. DipECVDI



**HOSPITAL NAME**

Truscott Animal  
Hospital

**REFERRING VET**

Mina Abdelsayed

**INVOICE**

51075

**DATE**

3-21-22

The information and recommendations provided are based on the images presented by the referring veterinarian/sonographer. No evaluation can be communicated regarding pathology that was not visible in the image/video clips provided.

Thank you for this referral. If the clinical or image interpretation does not parallel your findings or if I can be of any further assistance please contact me.

**Nele Eley**, DVM, Dr. med. vet., DipECVDI  
European Specialist in Veterinary Diagnostic Imaging, Cert. Radiology,  
Senior lecturer University of Giessen, Germany, Veterinary Faculty, Department of Radiology  
Nele.Eley@sonopath.com