



PATIENT

Lola Fragoso

SPECIES

Canine

BREED

Shihpoo

SEX

F

AGE

14Y

WEIGHT

6.4lbs

INTERPRETED BY

Nele Eley (Ondreka),
DVM Dr. med. vet.,
DipECVDI

IMAGING PERFORMED BY

Alondra Aviles Lopez
VT

HOSPITAL NAME

Veterinary Image Center

REFERRING VET

Dr. Amieiro, DVM

INVOICE

73991

DATE

3-2-26

PRESENTING CLINICAL SIGNS

- Presented on 2-24-2026 with CC of vomiting the previous night, eating less and fatigue or dyspneic. Lola was ADR and had dropped to 6.8 pounds from 8.5 pounds about 14 months ago. She had a heart murmur V/VI and Ronchi/crackles audible with mildly cyanotic mucus membranes. On X-rays showed pulmonary edema and possible pleural effusion. Tx Furosemide 10 mg IM and Dexameth 0.3cc IM and send home with furosemide PO to use 10mg q 2-8 hours. On 2-25-2026 ronchi no longer audible but breathing remains fast and shallow.

Abnormal PE/Chem/CBC/UA Results: CBC • PLT 507 (148-484) CHEM • GLOB 4.6 (2.5-4.5) • ALT 139 (10-125) • ALKP 522 (23-212)

COMPUTED TOMOGRAPHIC STUDY OF THE THORAX

Plain and post contrast studies are available for review.

COMPUTED TOMOGRAPHIC FINDINGS

The lungs are well expanded.

Mild multifocal ground glass interstitial pattern is present most prominently in the right and caudal lung lobes. The remaining lung parenchyma is unremarkable. No evidence of pulmonary nodules, masses, consolidation, or cavitation is seen. There is no evidence of effusion in the pleural spaces.

The heart and great vessels present within normal limits. The LA/Ao ratio is approximately 1:1. There is no evidence of pericardial effusion.

The mediastinal structures are unremarkable. There is no evidence of a thoracic masses or lymphadenopathy.

The thoracic boundaries are within age related normal limits.

COMPUTED TOMOGRAPHIC DIAGNOSIS

- Mild multifocal interstitial lung pattern with perihilar and caudal accentuation.
- No pleural effusion or pulmonary nodules/masses.
- Limited cardiac evaluation due to recent diuretic therapy. Mild left atrial enlargement cannot be excluded. The left atrium presents normal during CT examination.

INTERPRETATION OF FINDINGS & FURTHER RECOMMENDATIONS

The CT study reveals mild residual interstitial ground glass pattern in the perihilar and caudal lung regions which likely reflects resolving pulmonary edema. Interstitial inflammation and mild fibrosis cannot be ruled out entirely. Clinical correlation is recommended.

Presence of left atrial enlargement is not seen during CT. However, mild left atrial enlargement and pulmonary vascular dilation may be masked by recent diuretic therapy which limits the cardiac evaluation. Correlate with recent thoracic radiographs, cardiac ultrasound, and current clinical status. Continue monitoring respiratory rate effort and oxygenation. Consider echocardiography to assess left atrial size and cardiac function if persistent or progressive dyspnea occurs.



PATIENT

Lola Fragoso

SPECIES

Canine

BREED

Shihpoo

SEX

F

AGE

14Y

WEIGHT

6.4lbs

INTERPRETED BY

Nele Eley (Ondreka),
DVM Dr. med. vet.,
DipECVDI

IMAGING PERFORMED BY

Alondra Aviles Lopez
VT

HOSPITAL NAME

Veterinary Image Center

REFERRING VET

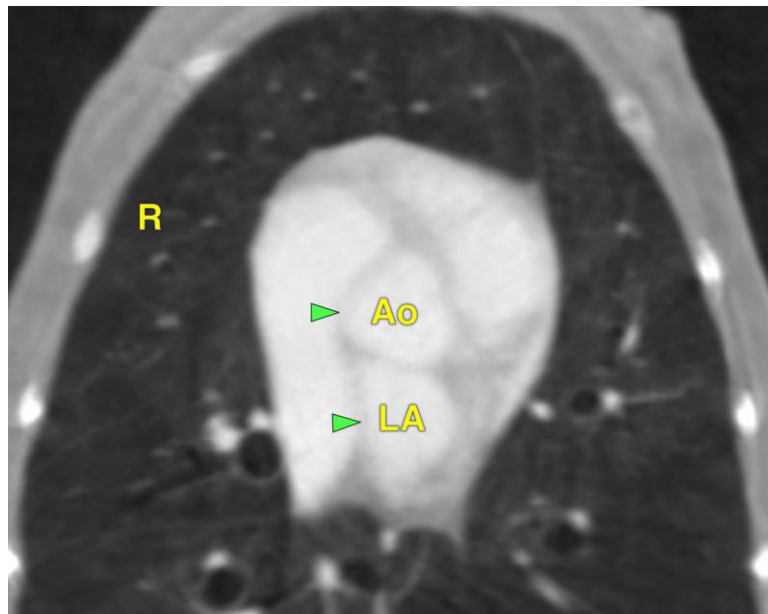
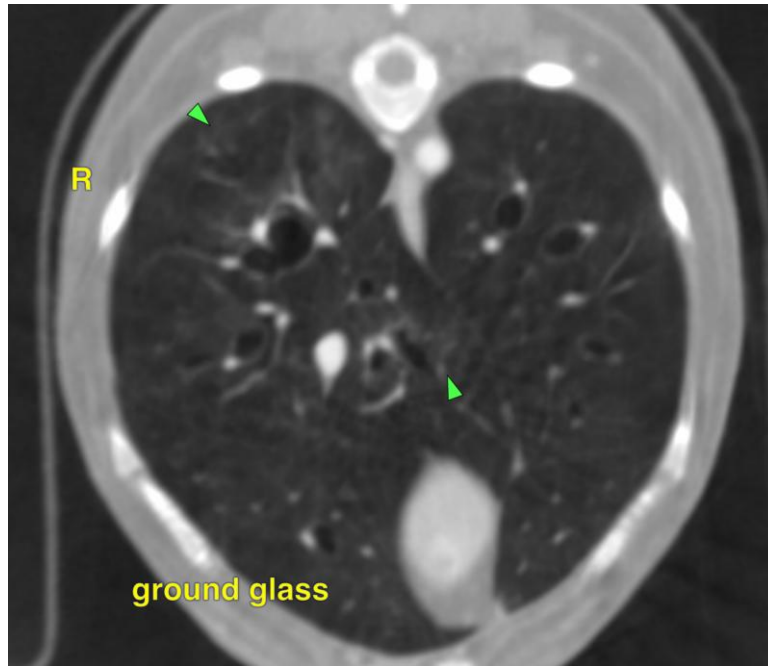
Dr. Amieiro, DVM

INVOICE

73991

DATE

3-2-26





PATIENT

Lola Fragoso

SPECIES

Canine

BREED

Shihpoo

SEX

F

AGE

14Y

WEIGHT

6.4lbs

INTERPRETED BY

Nele Eley (Ondreka),
DVM Dr. med. vet.,
DipECVDI

IMAGING PERFORMED BY

Alondra Aviles Lopez
VT

HOSPITAL NAME

Veterinary Image Center

REFERRING VET

Dr. Amieiro, DVM

INVOICE

73991

DATE

3-2-26

The information and recommendations provided are based on the images presented by the referring veterinarian. No evaluation can be communicated regarding pathology that was not visible in the image/video clips provided.

Thank you for this referral. If the clinical or image interpretation does not parallel your findings or if I can be of any further assistance please contact me.

Nele Eley (Ondreka), DVM, Dr. med. vet., DipECVDI

European Specialist in Veterinary Diagnostic Imaging, Cert. Radiology,

Senior lecturer University of Giessen/Germany, Veterinary Faculty, Department of Radiology.

info@sonopath.com