



## PATIENT

Cowboy Shprintz

## SPECIES

Canine

## BREED

Shih Tzu

## SEX

MN

## AGE

2Y

## WEIGHT

3.2kg

## INTERPRETED BY

Nele Eley (Ondreka),  
DVM Dr. med. vet.,  
DipECVDI

## IMAGING PERFORMED BY

Tabitha

## HOSPITAL NAME

Pet Emergency &  
Referral Center - NVA

## REFERRING VET

Dr. Kara Fiore

## INVOICE

73992

## DATE

3-2-26

## PRESENTING CLINICAL SIGNS

- History of elevated ALT. Bile acids and abdominal ultrasound suspicious for a portosystemic shunt but protein C is not consistent with a shunt.
- 01/22/2026 - Abdominal Ultrasound (Single Cavity study) - Right kidney length 3.4 cm, normal size/shape/architecture; Liver: single hyperechoic lesion 12 mm diameter in mid liver ventral to gallbladder. Conclusions: Imaging performed due to progressive ALT elevation; differentials listed include MVD vs extrahepatic shunt vs intrahepatic shunt vs toxin vs copper vs parasitic vs cholangiohepatitis vs cholecystitis vs other.
- 01/19/2026 - Abdominal ultrasound with Doppler - Findings: Right kidney 3.4 cm normal; Left kidney 3.2 cm normal; Liver: single hyperechoic lesion 12 mm diameter in mid liver ventral to gallbladder; Doppler: tortuous possible shunting vessel arising from portal vein, slightly larger than portal vein, terminating on caudal vena cava, consistent with possible single extrahepatic portophrenic portosystemic shunt; Gallbladder normal size with small amount of suspended hyperechoic debris; other abdominal organs within normal limits. Conclusions: Possible single extrahepatic portophrenic PSS; hepatic hyperechoic lesion 12 mm; recommendation: CT angiography to confirm shunt and further characterize lesion.
- 01/19/2026 - Protein C Activity Assay - Protein C 97% (RI 75-135%). Interpretation: Activities below 70% best cutoff to differentiate PSS from MVD; patient value within reference interval.

Abnormal PE/Chem/CBC/UA Results: 01/16/26 - Bile Acids Pre and Post - Fasting bile acids 77.5 µmol/L (HIGH; RI <13); Postprandial bile acids 103.5 µmol/L (HIGH; RI <25). Interpretive comments: Elevated fasting may occur with inadequate fasting/spontaneous gall bladder contraction/hepatobiliary disease; probability of hepatobiliary disease increases when fasting >25; elevated postprandial supportive of hepatobiliary disease; postprandial >100 often in PSS; note ursodeoxycholic acid may falsely elevate. 01/12/26 - Chemistry panel: ALT 313 U/L (HIGH; RI 10-125 or 12-118 depending on lab); Amylase 431 U/L (LOW; RI 500-1500); all else WNL 12/02/2025 - Adult Wellness Chemistryw/Lytes, SDMA: ALT (SGPT) 235 IU/L (HIGH; RI 12-118); Elevated ALT; otherwise within reference intervals.

## COMPUTED TOMOGRAPHIC STUDY OF THE ABDOMEN

Plain and post contrast studies are available for review.

## COMPUTED TOMOGRAPHIC FINDINGS

The serosal fat presents normal attenuation behavior. There is no evidence of peritoneal effusion or peritonitis.

Both kidneys present within normal limits for size, shape and organ architecture. After contrast administration, a bilaterally symmetric and uniform nephro- and pyelogram is noted.

The adrenal glands are within normal limits for size, shape and organ architecture.

The spleen presents with normal shape, even surface, uniformly attenuating parenchyma and homogeneous contrast enhancement, unremarkable.

Mild microhepatica is present. The hepatic parenchyma otherwise is uniform with no evidence of additional focal lesions beyond the noted hyperechoic nodule on ultrasound which appears benign and



## PATIENT

Cowboy Shprintz

## SPECIES

Canine

## BREED

Shih Tzu

## SEX

MN

## AGE

2Y

## WEIGHT

3.2kg

## INTERPRETED BY

Nele Eley (Ondreka),  
DVM Dr. med. vet.,  
DipECVDI

## IMAGING PERFORMED BY

Tabitha

## HOSPITAL NAME

Pet Emergency &  
Referral Center - NVA

## REFERRING VET

Dr. Kara Fiore

## INVOICE

73992

## DATE

3-2-26

not differentially enhancing on CT. No intrahepatic shunting vessels are identified. The extrahepatic portal vein and branches are normal in caliber and course. No evidence of extrahepatic portosystemic shunt is seen. There is no evidence of acquired portal vascular circulation.

The pancreas is evenly contoured; the pancreatic parenchyma is homogeneous and presents uniform contrast enhancement.

The position, delineation, wall and content of the gastrointestinal tract are considered within normal limits throughout.

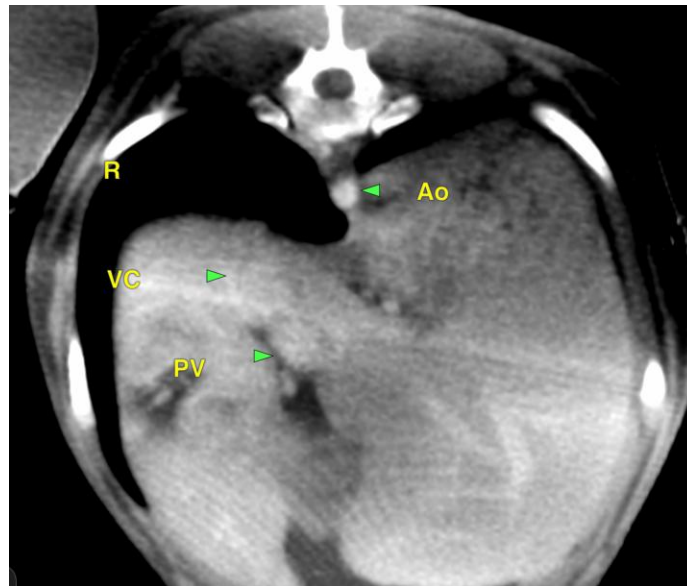
The bony and surrounding soft tissue structures reveal no abnormalities.

## COMPUTED TOMOGRAPHIC DIAGNOSIS

- Mild microhepatica - likely secondary to chronic hepatic dysfunction.
- No portosystemic shunt detected.
- Single small hepatic lesion unchanged.

## INTERPRETATION OF FINDINGS & FURTHER RECOMMENDATIONS

The patient's history of elevated ALT and abnormal bile acids is consistent with hepatocellular dysfunction, possibly associated with microhepatica or metabolic hepatopathy rather than a congenital portosystemic shunt. The CT angiography effectively excludes macroscopic shunting. Microvascular dysplasia and other hepatopathy including chronic hepatitis cannot be ruled out. Liver biopsy can be considered for further definition.





## PATIENT

Cowboy Shprintz

## SPECIES

Canine

## BREED

Shih Tzu

## SEX

MN

## AGE

2Y

## WEIGHT

3.2kg

## INTERPRETED BY

Nele Eley (Ondreka),  
DVM Dr. med. vet.,  
DipECVDI

## IMAGING PERFORMED BY

Tabitha

## HOSPITAL NAME

Pet Emergency &  
Referral Center - NVA

## REFERRING VET

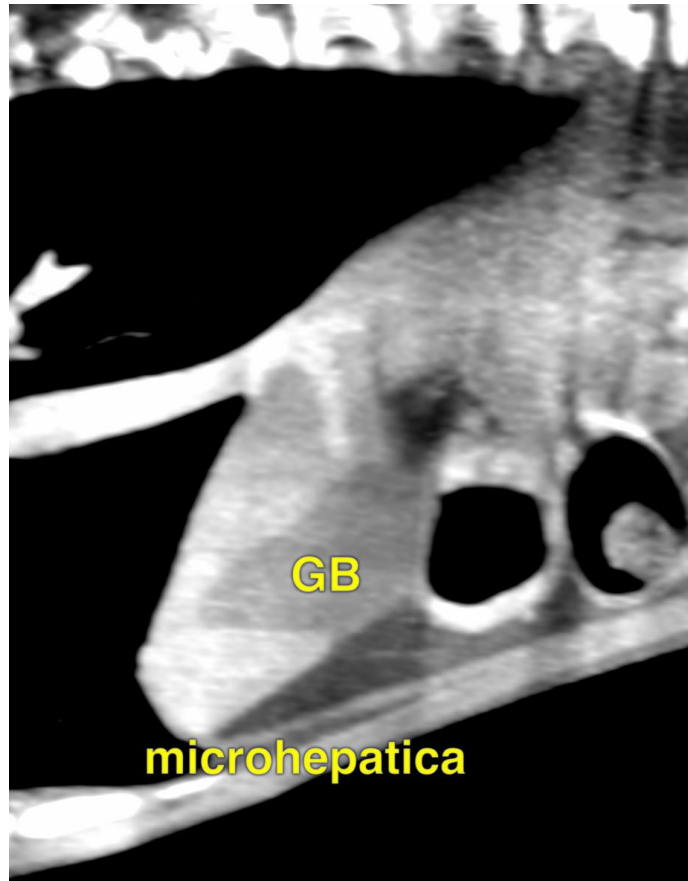
Dr. Kara Fiore

## INVOICE

73992

## DATE

3-2-26



The information and recommendations provided are based on the images presented by the referring veterinarian. No evaluation can be communicated regarding pathology that was not visible in the image/video clips provided.

Thank you for this referral. If the clinical or image interpretation does not parallel your findings or if I can be of any further assistance please contact me.

**Nele Eley (Ondreka)**, DVM, Dr. med. vet., DipECVDI

European Specialist in Veterinary Diagnostic Imaging, Cert. Radiology,  
Senior lecturer University of Giessen/Germany, Veterinary Faculty, Department of Radiology.

[info@sonopath.com](mailto:info@sonopath.com)