

**PATIENT**

Wizard Hall

**SPECIES**

Canine

**BREED**

Belgian Malinois

**SEX**

MN

**AGE**

5 Years

**INTERPRETED BY**Nele Eley, DVM  
Dr. med. Vet. DipECVDI**HOSPITAL NAME**Elizabeth Animal  
Hospital**REFERRING VET**

Leon Anderson, DVM

**INVOICE**

50709

**DATE**

3-2-22

**PRESENTING CLINICAL SIGNS**

Wizard has been vomiting. Michael hasn't seen him get into anything. He did spray round up around some grass and wire back in September of 21, but Wizard did eat some of the grass. The vomit was yellow the first time, now it is dark brown; it has no food in it. Michael says it looks like stool. He ate slow this morning but last night he ate well. Michael says that Wizard's stomach was very loud last night. No blood was visible per Michael.

Abnormal PE/Chem/CBC/UA Results: no abnormalities

**RADIOGRAPHIC STUDY OF THE ABDOMEN**

Right/left lateral and ventrodorsal views totaling 5 images available for review.

**RADIOGRAPHIC FINDINGS**

The abdominal serosal detail is maintained.

The stomach contains a moderate amount of mineral opaque material. No evidence of gastric dilation is seen. Two metal clips are seen within the gastric body or wall of the gastric body.

The small intestinal loops are nondilated. No overt plication is seen. Predominance of a gas pattern is noted.

A mild amount of fecal matter is seen within the colon.

**RADIOGRAPHIC DIAGNOSIS**

- Metal clips in the stomach / gastric wall.
- A moderate amount of gastric gravel.
- Small intestinal maldigestion pattern.

**INTERPRETATION OF THE FINDINGS & FURTHER RECOMMENDATIONS**

No radiographic evidence of mechanical ileus is seen. Functional ileus appears to be likely. The two small metal clips are either within the stomach or within the wall of the gastric body and they may be attached to other foreign material. However, no overt plication or other foreign material is seen.

The gastric gravel may indicate impaired gastric outflow, yet no significant dilation of the stomach is noted. Hence, the radiographic findings are equivocal in this context and further definition by means of ultrasound is strongly recommended in this patient, if not performed already, in order to rule out subileus and/or impaired gastric outflow.



**PATIENT**

Wizard Hall

**SPECIES**

Canine

**BREED**

Belgian Malinois

**SEX**

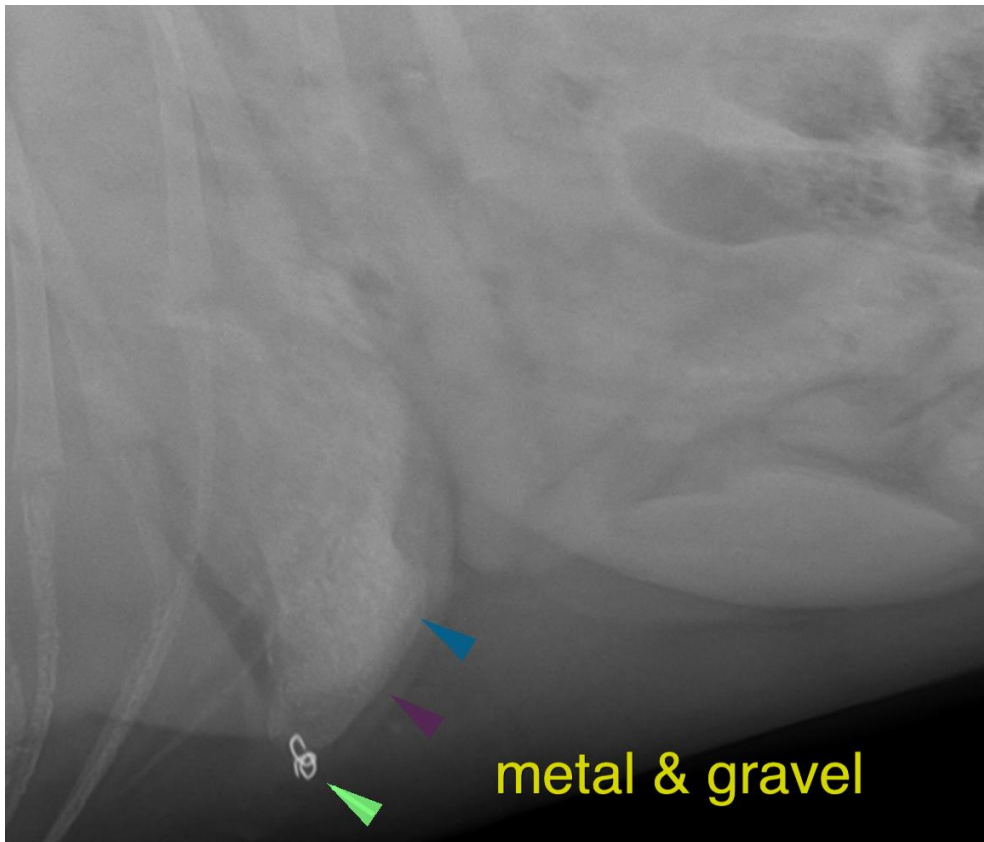
MN

**AGE**

5 Years

**INTERPRETED BY**

Nele Eley, DVM  
Dr. med. Vet. DipECVDI



**HOSPITAL NAME**

Elizabeth Animal  
Hospital

**REFERRING VET**

Leon Anderson, DVM

The information and recommendations provided are based on the images presented by the referring veterinarian/sonographer. No evaluation can be communicated regarding pathology that was not visible in the image/video clips provided.

Thank you for this referral. If the clinical or image interpretation does not parallel your findings or if I can be of any further assistance please contact me.

**Nele Eley**, DVM, Dr. med. vet., DipECVDI  
European Specialist in Veterinary Diagnostic Imaging, Cert. Radiology,  
Senior lecturer University of Giessen, Germany, Veterinary Faculty, Department of Radiology  
Nele.Eley@sonopath.com

**INVOICE**

50709

**DATE**

3-2-22