



PATIENT PRESENTING CLINICAL SIGNS

Puff Strauss *DVM pet. Chronic mild honking cough, sounds like reverse sneeze, but no inspiratory component. Sedated and visualized pharynx, appears to have cleft soft palate.
 Abnormal PE/Chem/CBC/UA Results: *DVM pet. During intubation, noted invagination of the soft palate.

SPECIES

Canine **COMPUTED TOMOGRAPHIC STUDY OF THE HEAD**

Plain and post contrast studies in open mouth position available for review.

BREED

Pomeranian **COMPUTED TOMOGRAPHIC FINDINGS**

Patient has a brachycephalic head conformation with shortened facial bones and dome shaped calvarium.

SEX

Neutered Male Reduced number and folding of the nasal turbinates is seen. There is rightward deviation of the nasal septum.

AGE

2 Years The hard and soft palate present within normal limits. The palatal veil appears to be long and mild concavity is seen in the caudal margin of the soft palate.

The left tympanic bulla is filled with fluid attenuating contrast negative material.

No structural abnormality of the larynx is noted.

INTERPRETED BY

Nele Eley (Ondreka), DVM Dr. med. vet., DipECVDI Flattening of the cervical trachea appears to be present.

COMPUTED TOMOGRAPHIC DIAGNOSIS

- Brachycephalic head conformation with upper airway stenosis.
- Left sided otitis media.
- Suspect dynamic tracheal disease.

HOSPITAL NAME

Mobile Pet Imaging **INTERPRETATION OF FINDINGS & FURTHER RECOMMENDATIONS**

The upper airways present typical for a brachycephalic dog. Elongation or other abnormality of the soft palate is a potential. No true cleft palate is seen.

REFERRING VET

Meaux The left sided otitis media may well be primary secretory secondary to stenosis of the auditory tube. Infectious otitis cannot be ruled out entirely.

INVOICE

50663 The flattening of the dorsal tracheal ligament may be incidental. However, dynamic tracheal disease cannot be ruled out.

DATE

3-2-22



PATIENT

Puff Strauss

SPECIES

Canine

BREED

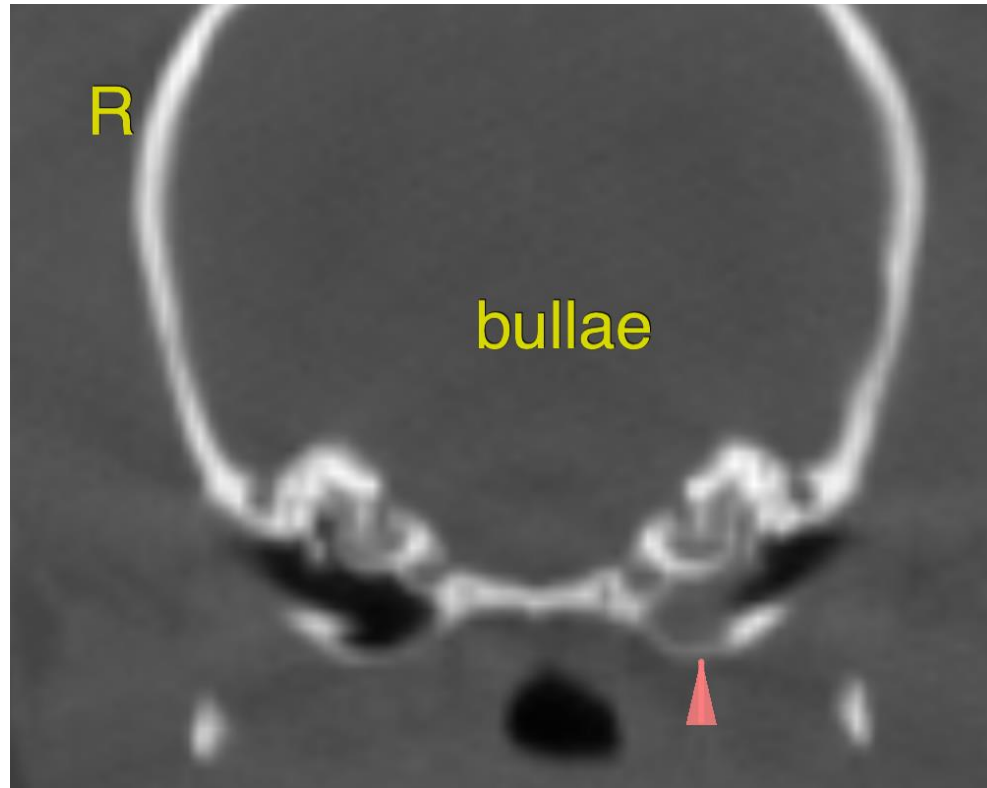
Pomeranian

SEX

Neutered Male

AGE

2 Years



INTERPRETED BY

Nele Eley (Ondreka),
DVM Dr. med. vet.,
DipECVDI

The information and recommendations provided are based on the images presented by the referring veterinarian. No evaluation can be communicated regarding pathology that was not visible in the image/video clips provided.

HOSPITAL NAME

Mobile Pet Imaging

Thank you for this referral. If the clinical or image interpretation does not parallel your findings or if I can be of any further assistance please contact me.

REFERRING VET

Meaux

Nele Eley (Ondreka), DVM, Dr. med. vet., DipECVDI
European Specialist in Veterinary Diagnostic Imaging, Cert. Radiology,
Senior lecturer University of Giessen/Germany, Veterinary Faculty, Department of Radiology.
Nele.Eley@sonopath.com

INVOICE

50663

DATE

3-2-22



PATIENT

Puff Strauss

SPECIES

Canine

BREED

Pomeranian

SEX

Neutered Male

AGE

2 Years

INTERPRETED BY

Nele Eley (Ondreka),
DVM Dr. med. vet.,
DipECVDI

HOSPITAL NAME

Mobile Pet Imaging

REFERRING VET

Meaux

INVOICE

50663

DATE

3-2-22