



PATIENT

Geordi Jaramillo

PRESENTING CLINICAL SIGNS

Reason for Visit: V/D/INAPPETENT/LETHARGIC History: 5YR OLD NEUTERED POODLE PRESENTED TODAY FOR ACUTE EPISODE OF VOMITING AND INAPPETENCE. C/S/V/D: V-HAS HELD DOWN WATER AFTER GIVING CERENIA LAST NIGHT

SPECIES

Canine

Abnormal PE/Chem/CBC/UA Results: CV/Respiratory: Normal heart rate and rhythm, no murmur, pulses strong and synchronous, normal bronchovesicular sounds. EENT: Clear OU and AU. No nasal discharge. No cough on tracheal palpation. Oral cavity: Mild to moderate dental tartar Musculoskeletal: BCS = 4/9. Ambulatory x 4 Uro/Perineum: No significant lesions Abd/GI: Soft, non-painful. Increased borborygmus. Firm structure on mid-abdomen. No fluid wave palpated Lymph Nodes: No peripheral lymphadenopathy Neurological: Alert and appropriate. No significant abnormalities Skin: Good hair coat. No ectoparasites seen Mentation: BAR Hydration: N

BREED

Poodle Mix

RADIOGRAPHIC STUDY OF THE ABDOMEN

SEX

Right/left lateral and ventrodorsal views of the abdomen totaling 3 images available for review.

NM

RADIOGRAPHIC FINDINGS

AGE

The abdominal serosal detail appears to be maintained.

5 Years, 2 Months

The stomach is empty.

INTERPRETED BY

Nele Eley, DVM
Dr. med. Vet. DipECVDI

Severe segmental dilation of the small intestine with predominance of gas content is seen. The dilated segment occupies most of the mid abdomen and is curved in appearance. Nondilated small intestinal segments are seen as well so that there are two populations of small bowel; a dilated and a nondilated population.

A mild amount of inspissated fecal material is seen in the caudal descending colon.

HOSPITAL NAME

DPC Veterinary Hospital

RADIOGRAPHIC DIAGNOSIS

- Mechanical small intestinal ileus with segmental dilation of the obstructed small intestine.

REFERRING VET

Dr. Rivera

INTERPRETATION OF THE FINDINGS & FURTHER RECOMMENDATIONS

The radiographic study is diagnostic for mechanical small intestinal ileus. Underlying causes include intussusception, nonradiopaque foreign material, obstruction, and other types of luminal or mural disease. Timely surgical exploration after stabilization of the patient is recommended if not performed already.

INVOICE

50698

DATE

3-2-22



PATIENT

Geordi Jaramillo

SPECIES

Canine

BREED

Poodle Mix

SEX

NM

AGE

5 Years, 2 Months

INTERPRETED BY

Nele Eley, DVM
Dr. med. Vet. DipECVDI

HOSPITAL NAME

DPC Veterinary
Hospital

REFERRING VET

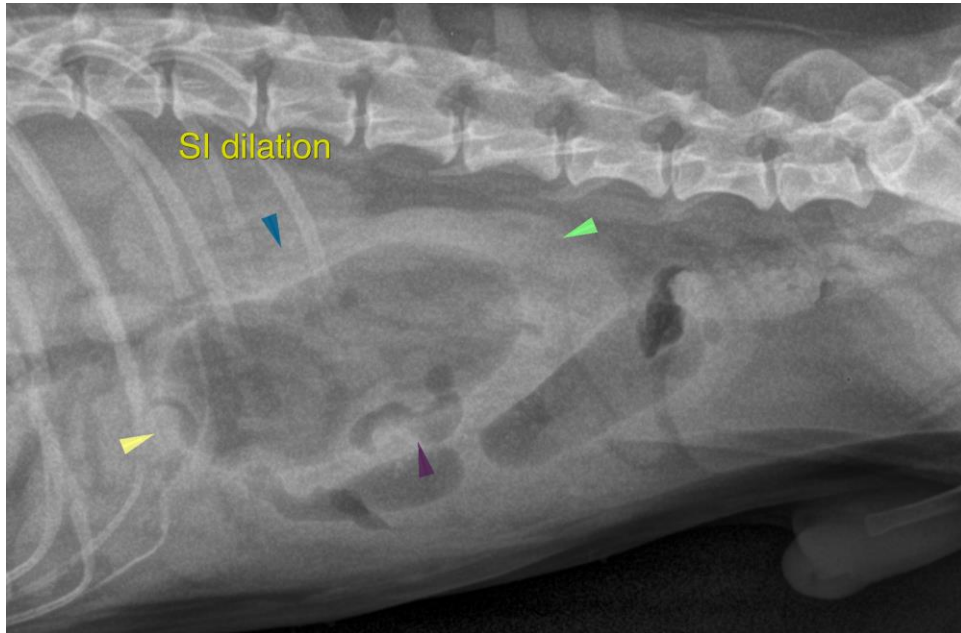
Dr. Rivera

INVOICE

50698

DATE

3-2-22



The information and recommendations provided are based on the images presented by the referring veterinarian/sonographer. No evaluation can be communicated regarding pathology that was not visible in the image/video clips provided.

Thank you for this referral. If the clinical or image interpretation does not parallel your findings or if I can be of any further assistance please contact me.

Nele Eley, DVM, Dr. med. vet., DipECVDI
European Specialist in Veterinary Diagnostic Imaging, Cert. Radiology,
Senior lecturer University of Giessen, Germany, Veterinary Faculty, Department of Radiology
Nele.Eley@sonopath.com