



PATIENT

Finnegan Dodds-Macie

PRESENTING CLINICAL SIGNS

Lameness RH leg for 4 weeks. Sore when she gets up.
 Abnormal PE/Chem/CBC/UA Results: Discomfort on palpation of right stifle, sits with stifle extended to side. Mild drawer palpable.

SPECIES

Canine

ULTRASONOGRAPHIC FINDINGS

Right Stifle

Mild periarticular osteophytosis, mild synovial swelling, and mild effusion are seen in the right stifle joint. The cranial cruciate ligament is continuous and well delineated. The internal echoarchitecture presents within normal limits. However, mild generalized swelling appears to be present. The lateral and medial menisci present within normal limits. The menisci are in situ, well delineated, and present uniform internal echogenicity.

BREED

Entlebucher Mountain Dog

Left Stifle

SEX

FS

No abnormal effusion is seen within the supra- and infra patellar area. There is no evidence of synovial or capsular thickening or proliferation. The cranial cruciate ligament appears to be continuous and well-delineated, no deviation from normal echoarchitecture is noted. Lateral and medial menisci are within their anticipated positions and align well below the bone surfaces, meniscal surfaces are even and smooth. The echotexture is hypo echoic and uniform. The joint margins are smooth, no osteophytes are seen. The infra patellar fat pad presents the expected echo architecture.

AGE

4 Years

ULTRASONOGRAPHIC DIAGNOSIS

- No evidence of cranial cruciate ligament injury in the right and left stifle.
- Mild osteoarthritis of the right stifle.

INTERPRETED BY

Nele Eley, DVM
 Dr. med. Vet. DipECVDI

INTERPRETATION OF THE FINDINGS & FURTHER RECOMMENDATIONS

Definitive fiber disruption of the cranial cruciate ligament cannot be demonstrated ultrasonographically despite the presence of mild osteoarthritic findings and clinical laxity. The findings suggest presence of cranial cruciate ligament edema. Early pre-stage of partial rupture cannot be ruled out; however, is not definitive per the ultrasonographic examination at this point. The left stifle presents within normal limits.

HOSPITAL NAME

Cedarview Animal Hospital

REFERRING VET

Dr. Christie Limbrick

INVOICE

50685

DATE

3-2-22



PATIENT

Finnegan Dodds-
Macie

SPECIES

Canine

BREED

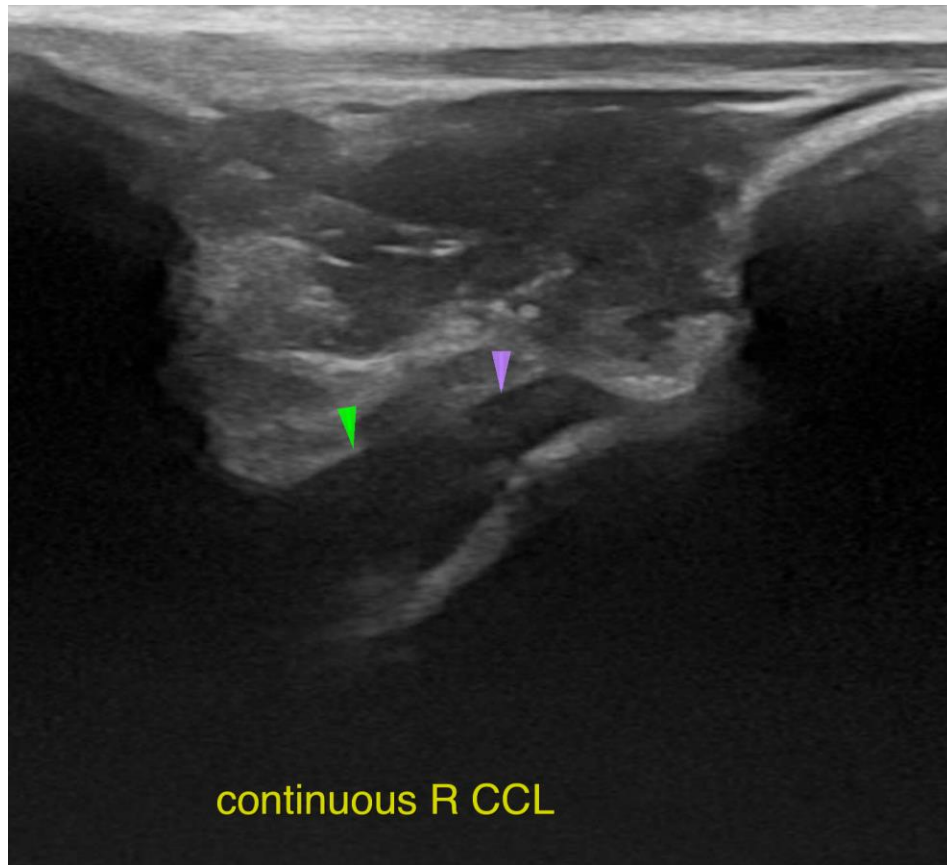
Entlebucher
Mountain Dog

SEX

FS

AGE

4 Years



continuous R CCL

INTERPRETED BY

Nele Eley, DVM
Dr. med. Vet. DipECVDI

The information and recommendations provided are based on the images presented by the referring veterinarian/sonographer. No evaluation can be communicated regarding pathology that was not visible in the image/video clips provided.

HOSPITAL NAME

Cedarview Animal
Hospital

Thank you for this referral. If the clinical or image interpretation does not parallel your findings or if I can be of any further assistance please contact me.

Nele Eley, DVM, Dr. med. vet., DipECVDI
European Specialist in Veterinary Diagnostic Imaging, Cert. Radiology,
Senior lecturer University of Giessen, Germany, Veterinary Faculty, Department of Radiology
Nele.Eley@sonopath.com

REFERRING VET

Dr. Christie Limbrick

INVOICE

50685

DATE

3-2-22