

**PATIENT**

Peanut Kelly

PRESENTING CLINICAL SIGNS

P has been having issues with his right ear for 2 months. Took a good look in P's ear last week, while under for neuter, suspected a polyp, and tried to pull it out, but too far in the ear. Performed head CT today to see where the polyp was, and if P needed a VBO. Suspect osteomyelitis and possibly a bad deep inner ear infection.

SPECIES

Feline

COMPUTED TOMOGRAPHIC STUDY OF THE HEAD

Plain and post contrast studies available for review.

BREED

DSH

COMPUTED TOMOGRAPHIC FINDINGS

The right tympanic bulla is filled with hypoattenuating material with peripheral rim enhancement. Moderate irregular thickening of the osseous lining of the right tympanic bulla is seen. The right tympanic bulla is expanded. Mild peripheral soft tissue swelling is noted.

SEX

MN

There is mild regional thickening and enhancement of the meninges.

Mild osteolytic changes of the skull base and sclerosis of the petrous temporal bone are noted.

AGE

6 Months

The right retropharyngeal lymph node presents moderate symmetric enlargement with increased contrast enhancement.

INTERPRETED BY

Nele Eley, DVM
Dr. med. Vet. DipECVDI

COMPUTED TOMOGRAPHIC DIAGNOSIS

- Chronic right hand sided otitis media with tympanokeratoma formation and intracranial extension with reactive meningitis.
- Right medial retropharyngeal lymphadenitis.

HOSPITAL NAME

Catskill Veterinary
Services, PLLC

INTERPRETATION OF THE FINDINGS & FURTHER RECOMMENDATIONS

The CT findings are compatible with tympanokeratoma (formally known as cholesteatoma or cholesterol granuloma) of the right middle ear as a consequence of chronic otitis media. There is evidence of intracranial extension with mild regional meningitis and regional lymphadenitis. Ventral bulla osteotomy is indicated in order to address the keratoma/ granuloma formation.

REFERRING VET

Dr. Joseph
D'Abbraccio

INVOICE

57236

DATE

3-14-23



PATIENT

Peanut Kelly

SPECIES

Feline

BREED

DSH

SEX

MN

AGE

6 Months

INTERPRETED BY

Nele Eley, DVM
Dr. med. Vet. DipECVDI

HOSPITAL NAME

Catskill Veterinary
Services, PLLC

REFERRING VET

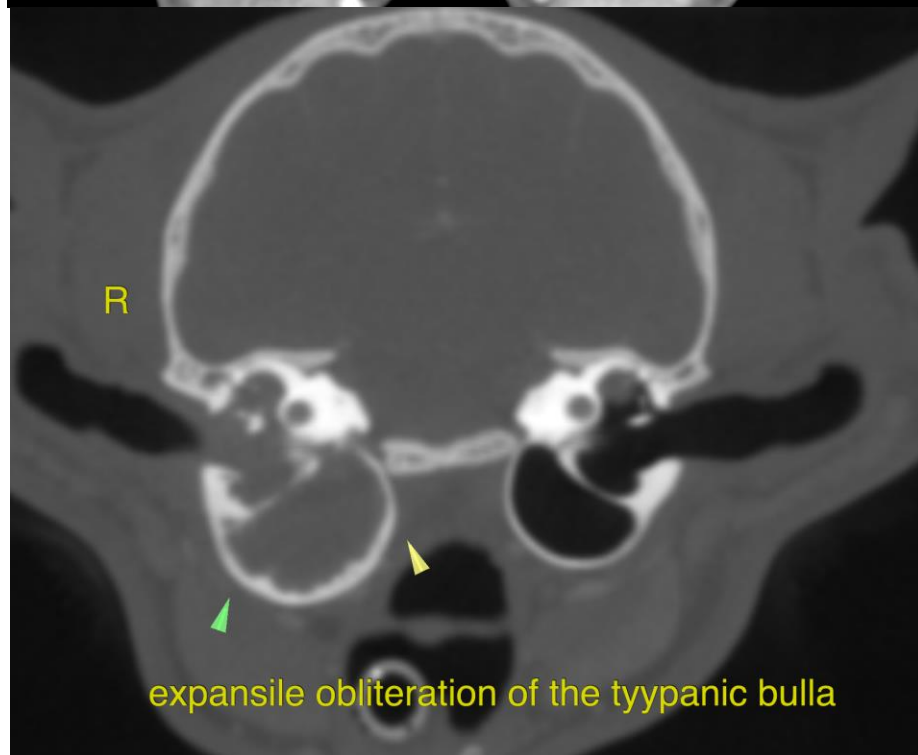
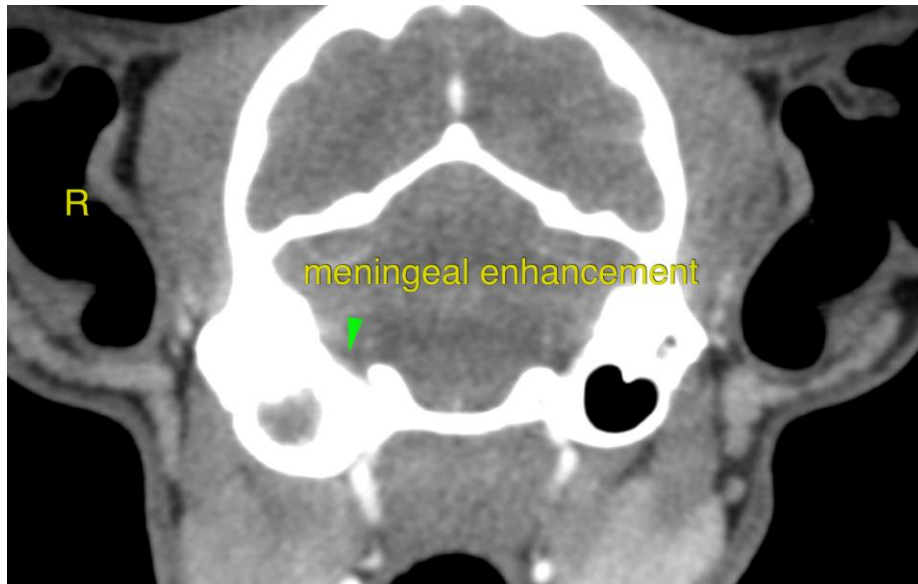
Dr. Joseph
D'Abbraccio

INVOICE

57236

DATE

3-14-23





PATIENT

Peanut Kelly

The information and recommendations provided are based on the images presented by the referring veterinarian/sonographer. No evaluation can be communicated regarding pathology that was not visible in the image/video clips provided.

SPECIES

Feline

Thank you for this referral. If the clinical or image interpretation does not parallel your findings or if I can be of any further assistance please contact me.

Nele Eley, DVM, Dr. med. vet., DipECVDI
European Specialist in Veterinary Diagnostic Imaging, Cert. Radiology,
Senior lecturer University of Giessen, Germany, Veterinary Faculty, Department of Radiology
Nele.Eley@sonopath.com

BREED

DSH

SEX

MN

AGE

6 Months

INTERPRETED BY

Nele Eley, DVM
Dr. med. Vet. DipECVDI

HOSPITAL NAME

Catskill Veterinary
Services, PLLC

REFERRING VET

Dr. Joseph
D'Abbraccio

INVOICE

57236

DATE

3-14-23