

**PATIENT**

Tide Dayton

**PRESENTING CLINICAL SIGNS**

Swelling around lower right canine tooth

**SPECIES**

Canine

**COMPUTED TOMOGRAPHIC STUDY OF THE HEAD**

Plain and post contrast studies available for review.

**BREED**

Labrador Ret.

**COMPUTED TOMOGRAPHIC FINDINGS**

An ovoid soft tissue attenuating mass of approximately 1.5 cm diameter is seen in the right rostral mandible associated with the triadan 404. Expansile moth eaten osteolysis with bubbly appearance is seen in the rostral and buccal direction starting from the distal margin of the triadan 403 and extending up to the mesial margin of the triadan 406. The expansile osteolytic changes do involve the periodontium of the triadan 404. The remainder of the dentition presents within age related normal limits.

**SEX**

MN

**COMPUTED TOMOGRAPHIC DIAGNOSIS**

- Soft tissue mass at the gingivostomal margin of the triadan 404 with expansile moderately aggressive osteolysis of the right rostral mandible.

**AGE**

4 Years

**INTERPRETATION OF THE FINDINGS & FURTHER RECOMMENDATIONS**

The CT study reveals a soft tissue mass emerging from the gingivostomal margin of the right rostral mandible associated with the triadan 404 which presents expansile moderately aggressive osteolytic changes with a long transition zone in the right rostral mandible. Acanthomatous epulis / ameloblastoma is the primary differential diagnosis. Oral fibrosarcoma, fibroma, squamous cell carcinoma, melanoma, and other soft tissue neoplasia are potential differential diagnoses. Final diagnosis will require sampling for histology which should be considered if not performed already in this patient.

**INTERPRETED BY**Nele Eley, DVM  
Dr. med. Vet. DipECVDI**HOSPITAL NAME**Animal Medical  
Center of Mt.  
Pleasant**REFERRING VET**

Anne Briley, DVM

**INVOICE**

57207

**DATE**

3-13-23



**PATIENT**

Tide Dayton

**SPECIES**

Canine

**BREED**

Labrador Ret.

**SEX**

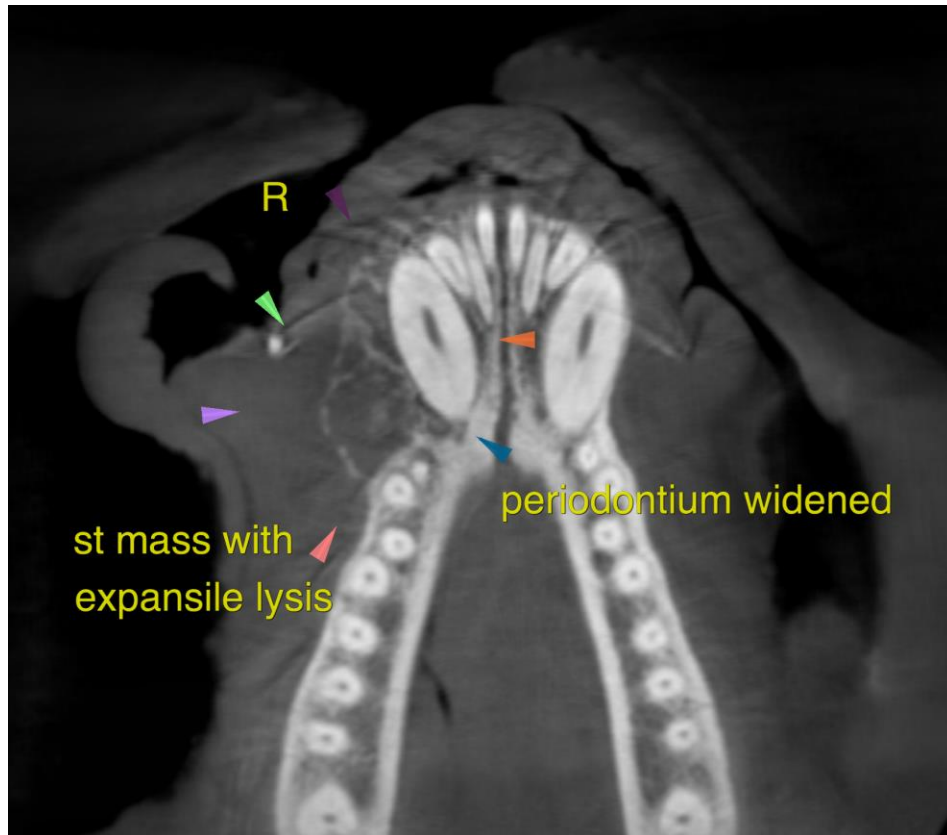
MN

**AGE**

4 Years

**INTERPRETED BY**

Nele Eley, DVM  
Dr. med. Vet. DipECVDI



**HOSPITAL NAME**

Animal Medical  
Center of Mt.  
Pleasant

**REFERRING VET**

Anne Briley, DVM

**INVOICE**

57207

**DATE**

3-13-23

The information and recommendations provided are based on the images presented by the referring veterinarian/sonographer. No evaluation can be communicated regarding pathology that was not visible in the image/video clips provided.

Thank you for this referral. If the clinical or image interpretation does not parallel your findings or if I can be of any further assistance please contact me.

**Nele Eley**, DVM, Dr. med. vet., DipECVDI  
European Specialist in Veterinary Diagnostic Imaging, Cert. Radiology,  
Senior lecturer University of Giessen, Germany, Veterinary Faculty, Department of Radiology  
Nele.Eley@sonopath.com