



**PATIENT**

Bliss Dostal

**PRESENTING CLINICAL SIGNS**

History of mass in mouth. Pending histopathology but owners wanted met check on thorax incase of neoplasia.

**SPECIES**

Canine

**COMPUTED TOMOGRAPHIC STUDY OF THE THORAX**

Plain study available for review.

**BREED**

Golden Retriever

**COMPUTED TOMOGRAPHIC FINDINGS**

The bony and surrounding soft tissue structures are within normal limits.

The sternal, cranial mediastinal and tracheobronchial lymph nodes are small elongated with a normal short-to-long-axis-ratio.

**SEX**

FS

The cardiovascular structures including the pulmonary vasculature are within normal limits.

A 20 x 15mm sized soft tissue attenuating nodule is seen peripherally and ventrally within the right middle lung lobe. The parenchyma of the remainder of the lung lobes presents within age related normal limits. No additional nodules or masses are seen.

**AGE**

9.5 Years

Small incidental gas pockets are seen within the esophageal lumen, there is no evidence of abnormal dilation.

**INTERPRETED BY**

Nele Eley, DVM  
Dr. med. Vet. DipECVDI

**COMPUTED TOMOGRAPHIC DIAGNOSIS**

- Single soft tissue nodule within the ventral aspect of the right middle lung lobe.

**HOSPITAL NAME**

Scottsdale Veterinary  
Clinic

**INTERPRETATION OF THE FINDINGS & FURTHER RECOMMENDATIONS**

The CT study reveals a single soft tissue nodule within the ventral aspect of the right middle lung lobe. Differential diagnosis includes secondary neoplasia of the lung such as metastases or round cell neoplasia / sarcoma primarily. Primary neoplasia of the lung, pneumonic infiltrate, fibrotic nodule, and other cannot be ruled out entirely but is thought less likely. The nodule is unfortunately not well accessible for ultrasound guided sampling. Further monitoring by means of CT (radiographs may fail to image this region of the lung optimally) versus lung lobectomy could be discussed.

**REFERRING VET**

Dr. Horsley

**INVOICE**

57214

**DATE**

3-13-23



**PATIENT**

Bliss Dostal

**SPECIES**

Canine

**BREED**

Golden Retriever

**SEX**

FS

**AGE**

9.5 Years

**INTERPRETED BY**

Nele Eley, DVM  
Dr. med. Vet. DipECVDI

**HOSPITAL NAME**

Scottsdale Veterinary  
Clinic

**REFERRING VET**

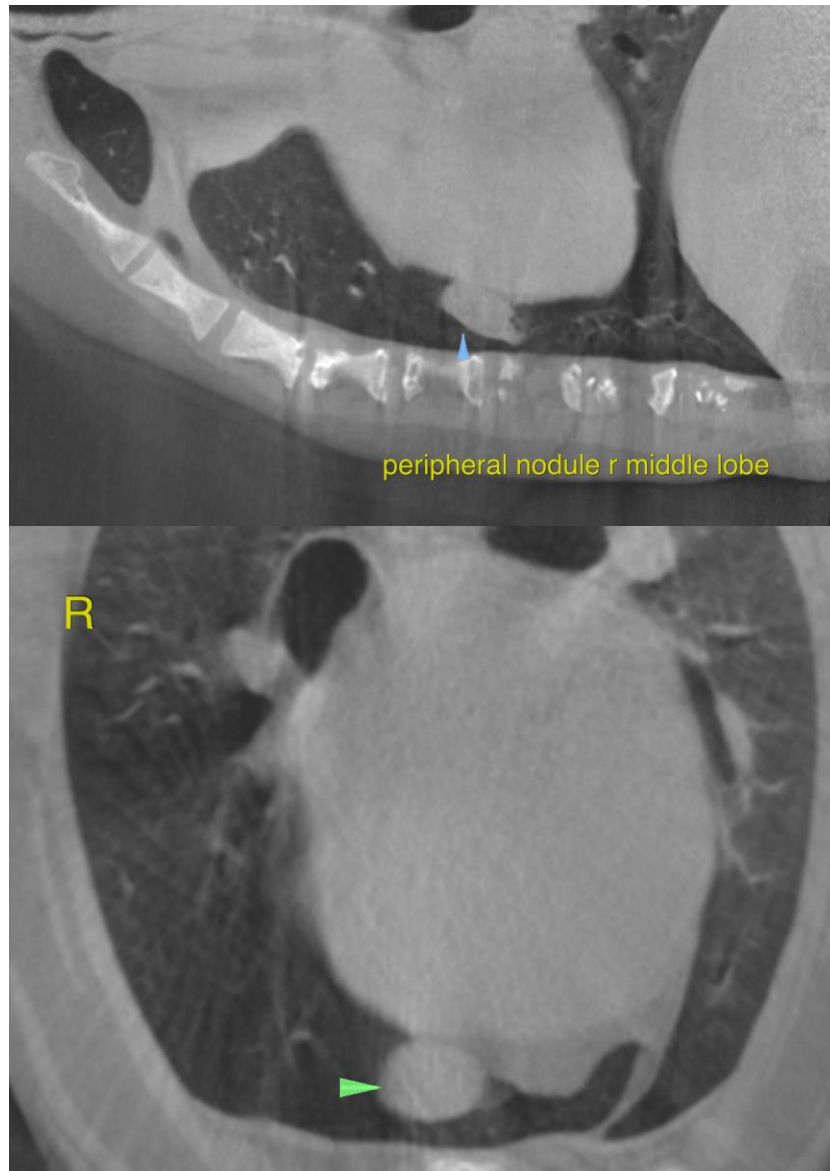
Dr. Horsley

**INVOICE**

57214

**DATE**

3-13-23



The information and recommendations provided are based on the images presented by the referring veterinarian/sonographer. No evaluation can be communicated regarding pathology that was not visible in the image/video clips provided.

Thank you for this referral. If the clinical or image interpretation does not parallel your findings or if I can be of any further assistance please contact me.

**Nele Eley**, DVM, Dr. med. vet., DipECVDI  
European Specialist in Veterinary Diagnostic Imaging, Cert. Radiology,  
Senior lecturer University of Giessen, Germany, Veterinary Faculty, Department of Radiology  
Nele.Eley@sonopath.com