



PATIENT

Abby Frontera

PRESENTING CLINICAL SIGNS

Referred for ct scan, patient presented after an acute onset of tetraparalysis with no deep pain.

SPECIES

K9

COMPUTED TOMOGRAPHIC STUDY OF THE CERVICAL SPINE

Plain study in soft tissue and bone windows and myelogram with cervical puncture in bone window available for review.

BREED

Shihtzu

COMPUTED TOMOGRAPHIC FINDINGS

Moderate intervertebral disc space narrowing is seen between C4/5, C5/6, and C6/7.

SEX

Female

Mild intervertebral disc hernias with mild dorsal deviation of the ventral contrast space are seen between C4/5 and C6/7.

Moderate extrusion of intervertebral disc material within the ventral epidural space with slight shift to the left of the midline is seen between C5 and C6. The spinal cord is deviated and compressed dorsally. The ventral and dorsal contrast spaces are significantly reduced.

AGE

12

The in situ intervertebral disc C6/7 presents a vacuum phenomenon as an expression of chronic degenerative disc disease.

Left hand sided otitis media is noted.

INTERPRETED BY

Nele Eley, DVM
Dr. med. Vet. DipECVDI

COMPUTED TOMOGRAPHIC DIAGNOSIS

- Acute moderately compressive intervertebral disc extrusion C5/6.
- Chronic mild intervertebral disc protrusions and degenerative disc disease between C4/5 and C6/7.

HOSPITAL NAME

Juana Diaz Animal
Hospital

INTERPRETATION OF THE FINDINGS & FURTHER RECOMMENDATIONS

The CT findings are compatible with acute extrusion and moderate spinal cord compression between C5 and C6. The volume of the extruded material is slightly larger to the left of the midline within the ventral epidural space of the vertebral canal. Decompressive surgery is indicated based on the degree of spinal cord compression.

REFERRING VET

Jose Rivera

Note the presence of presumably chronic mildly compressive intervertebral disc herniation in the neighboring intervertebral disc spaces between C4/5 and C6/7.

INVOICE

57208

DATE

3-13-23



PATIENT

Abby Frontera

SPECIES

K9

BREED

Shihtzu

SEX

Female

AGE

12

INTERPRETED BY

Nele Eley, DVM
Dr. med. Vet. DipECVDI

HOSPITAL NAME

Juana Diaz Animal
Hospital

REFERRING VET

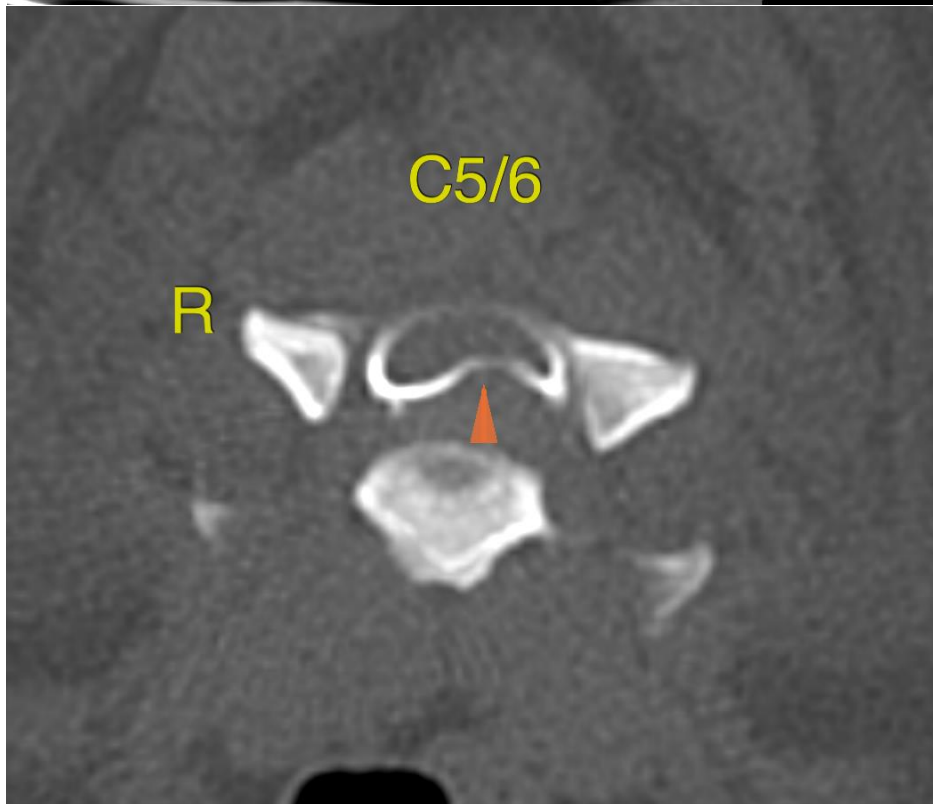
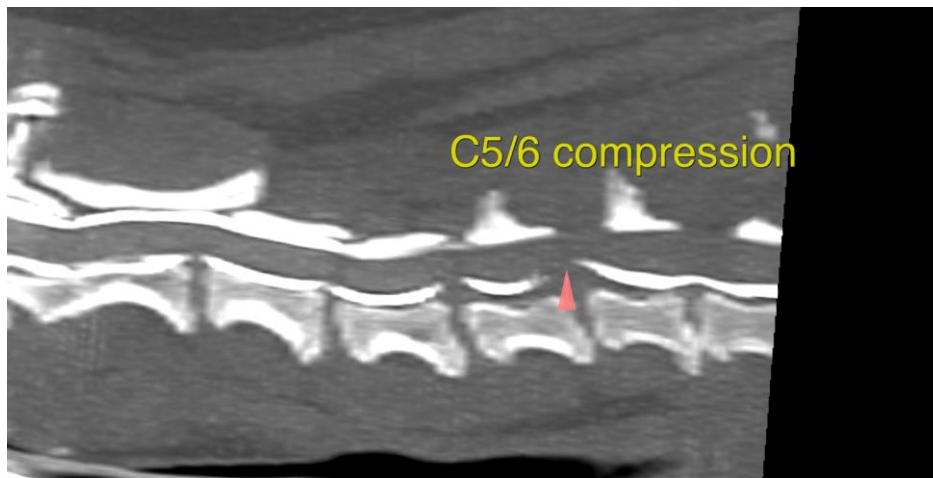
Jose Rivera

INVOICE

57208

DATE

3-13-23





PATIENT

Abby Frontera

The information and recommendations provided are based on the images presented by the referring veterinarian/sonographer. No evaluation can be communicated regarding pathology that was not visible in the image/video clips provided.

Thank you for this referral. If the clinical or image interpretation does not parallel your findings or if I can be of any further assistance please contact me.

SPECIES

K9

Nele Eley, DVM, Dr. med. vet., DipECVDI
European Specialist in Veterinary Diagnostic Imaging, Cert. Radiology,
Senior lecturer University of Giessen, Germany, Veterinary Faculty, Department of Radiology
Nele.Eley@sonopath.com

BREED

Shihtzu

SEX

Female

AGE

12

INTERPRETED BY

Nele Eley, DVM
Dr. med. Vet. DipECVDI

HOSPITAL NAME

Juana Diaz Animal
Hospital

REFERRING VET

Jose Rivera

INVOICE

57208

DATE

3-13-23