



PATIENT

Marley Cordero

SPECIES

Canine

BREED

Australian Cattle Dog
Mixed

SEX

FS

AGE

7Y

WEIGHT

52lbs

INTERPRETED BY

Nele Eley (Ondreka),
DVM Dr. med. vet.,
DipECVDI

IMAGING PERFORMED BY

Alondra Aviles Lopez VT

HOSPITAL NAME

Veterinary Image Center

REFERRING VET

Dra. Martinez, DVM

INVOICE

74168

DATE

3-12-26

PRESENTING CLINICAL SIGNS

- Patient presented to the hospital after experiencing three consecutive seizure episodes today, with the last seizure occurring upon
- arrival to the hospital. Patient was previously presented to our hospital at the end of February after experiencing the first seizure episode. At that time, treatment was initiated with Keppra ER 750 mg PO q12h. Following initiation of anticonvulsant therapy, the patient remained
- seizure-free for approximately two weeks until the recurrence of seizure activity today.

Abnormal PE/Chem/CBC/UA Results: CBC: WNL CHEM: PHOS High

COMPUTED TOMOGRAPHIC STUDY OF THE HEAD

Plain and post contrast studies are available for review.

COMPUTED TOMOGRAPHIC FINDINGS

Within the left cerebral hemisphere, there is a poorly defined intraaxial mass effect characterized by generalized parenchymal expansion and effacement of adjacent sulci. Marked rightward midline shift of the cerebral midline indicating significant mass effect and intracranial pressure increase is noted. The left lateral ventricle appears to be slit like. No definitive abnormal contrast enhancement is identified. No evidence of intracranial hemorrhage or mineralization can be seen on the current study. The calvarium and skull base appear intact.

Thin and smoothly folded conchae and turbinates with even smooth mucosal lining. The osseous lining of the nasal cavities is intact.

Both temporomandibular joints present congruent joint spaces with even subchondral bone surfaces and are considered within normal limits.

Both tympanic bullae are aerated, the mucosal lining is not seen, the bony wall is smooth and thin. The external auditory meatuses present within normal limits.

The submandibular and medial retropharyngeal lymph nodes are small and elongated with a normal short-to-long-axis-ratio is < 0.5, the attenuation and contrast enhancement pattern is uniform.

The salivary glands present within normal limits.

The visible dentition is within normal limits.

COMPUTED TOMOGRAPHIC DIAGNOSIS

- Intraaxial mass effect on the left cerebral hemisphere with rightward midline shift and no appreciable contrast enhancement.

INTERPRETATION OF FINDINGS & FURTHER RECOMMENDATIONS

The CT study reveals space occupying intraaxial lesion with substantial midline shift and no appreciable contrast enhancement suggesting either an infiltrative neoplastic or inflammatory process or intraaxial edema in conjunction with cerebrovascular disease. Primary differential diagnoses are intracranial neoplasia, inflammatory or infectious meningoencephalitis, subacute infarction with vasogenic edema, and other edema. MRI of the brain is strongly recommended for further characterization of the lesion. Medical management for increased intracranial pressure could be



PATIENT

Marley Cordero

SPECIES

Canine

BREED

Australian Cattle Dog
Mixed

SEX

FS

AGE

7Y

WEIGHT

52lbs

INTERPRETED BY

Nele Eley (Ondreka),
DVM Dr. med. vet.,
DipECVDI

IMAGING PERFORMED BY

Alondra Aviles Lopez VT

HOSPITAL NAME

Veterinary Image Center

REFERRING VET

Dra. Martinez, DVM

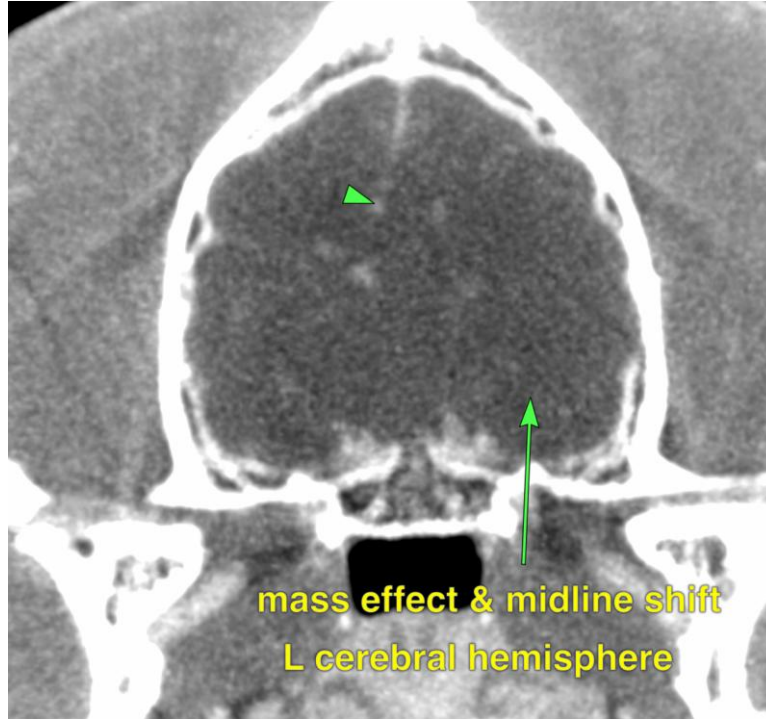
INVOICE

74168

DATE

3-12-26

considered depending on the clinical correlation.



The information and recommendations provided are based on the images presented by the referring veterinarian. No evaluation can be communicated regarding pathology that was not visible in the image/video clips provided.

Thank you for this referral. If the clinical or image interpretation does not parallel your findings or if I can be of any further assistance please contact me.

Nele Eley (Ondreka), DVM, Dr. med. vet., DipECVDI
European Specialist in Veterinary Diagnostic Imaging, Cert. Radiology,
Senior lecturer University of Giessen/Germany, Veterinary Faculty, Department of Radiology.
info@sonopath.com