

Diagnostic Imaging

Veterinary CT, Ultrasound & Telectology Services
veterinarian referral only

PATIENT PRESENTING CLINICAL SIGNS

- Ella Campeas**
- Persistent Sneezing, Reverse sneezing
 - Hydroxyzine 25mg bid
 - Pt presents for f/u on coughing/reverse sneezing. O said cough and reverse sneezing has decreased but has not fully gone away and is now snoring when she hasn't before. O is concerned something is stuck in the Pt's

SPECIES

Canine

COMPUTED TOMOGRAPHIC STUDY OF THE HEAD

BREED

Plain and post contrast studies are available for review.

Terrier Mix

COMPUTED TOMOGRAPHIC FINDINGS

SEX

Female Spayed

The brain presents no deviation from normal anatomy and symmetry. The grey and white matter distinction and the neuroparenchymal attenuation are as expected. The distribution of contrast enhancement is within normal limits throughout the parenchyma and meninges. The ventricular system is non-dilated and within the limits of the expected volume and symmetry.

AGE

5Y

Within both nasal cavities, there is moderate multifocal accumulation of fluid attenuating material associated with mucosal swelling. The frontal sinuses show mild mucosal thickening. No nasal foreign material is seen. The nasal turbinates are preserved. There is no focal mass or aggressive bone lysis. A small amount of fluid is present within the nasopharynx. The caudal nasopharyngeal lumen is collapsed. Evidence of nasopharyngeal stenosis is not seen.

INTERPRETED BY

Nele Eley (Ondreka),
DVM Dr. med. vet.,
DipECVDI

Both temporomandibular joints present congruent joint spaces with even subchondral bone surfaces and are considered within normal limits.

Both tympanic bullae are aerated, the mucosal lining is not seen, the bony wall is smooth and thin. The external auditory meatuses present within normal limits.

The retropharyngeal lymph nodes are mildly enlarged.

HOSPITAL NAME

Rockaway Animal
Hospital

The tonsils are mildly enlarged bilaterally.

The salivary glands present within normal limits.

The visible dentition is within normal limits.

REFERRING VET

Dr. Salazar

COMPUTED TOMOGRAPHIC DIAGNOSIS

INVOICE

74171

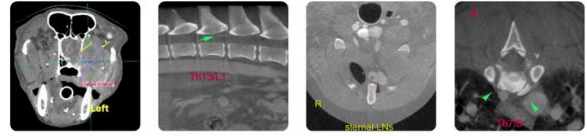
- Moderate bilateral rhinosinusitis.
- Mild nasopharyngeal fluid.
- Mild reactive retropharyngeal lymphadenomegaly.
- Mild bilateral tonsillitis.
- No CT evidence of nasal foreign body, mass lesion, or destructive sinonasal disease.

INTERPRETATION OF FINDINGS & FURTHER RECOMMENDATIONS

DATE

3-12-26

The imaging findings are most consistent with inflammatory rhinosinusitis. Possible underlying



Diagnostic Imaging

Veterinary CT, Ultrasound & Telectology Services
veterinarian referral only

PATIENT

Ella Campeas

causes include allergic / inflammatory rhinosinusitis, chronic infectious rhinitis such as bacterial or viral infection, and less likely occult foreign body. Post-nasal inflammatory drainage may explain the nasopharyngeal fluid and snoring. Dynamic nasopharyngeal collapse is a possible but uncommon differential diagnosis. Rhinoscopy with nasal flushing and sampling for culture and cytology is recommended if not performed already.

SPECIES

Canine

BREED

Terrier Mix

SEX

Female Spayed

AGE

5Y

INTERPRETED BY

Nele Eley (Ondreka),
DVM Dr. med. vet.,
DipECVDI

HOSPITAL NAME

Rockaway Animal
Hospital

REFERRING VET

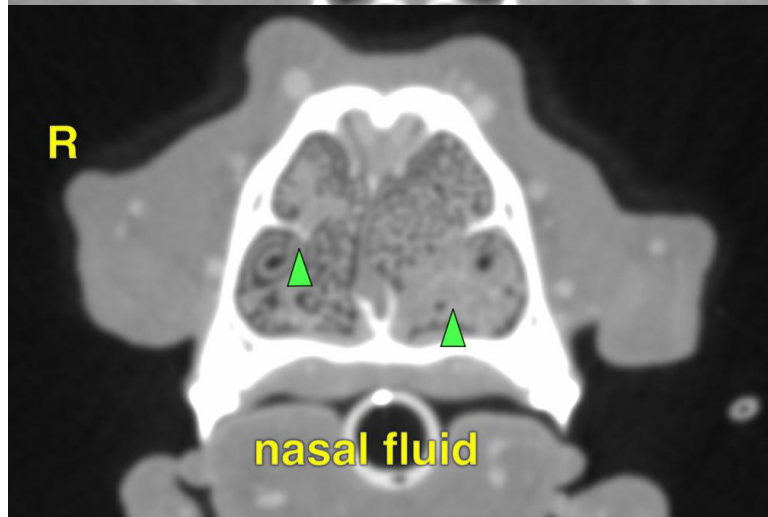
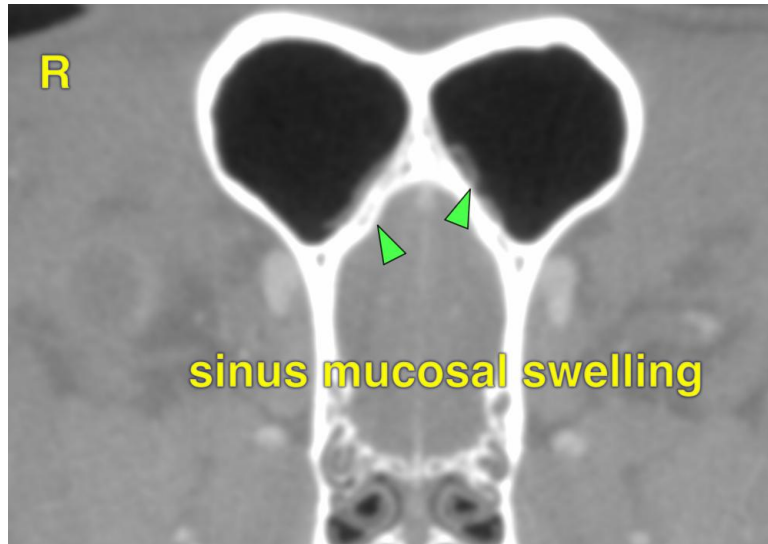
Dr. Salazar

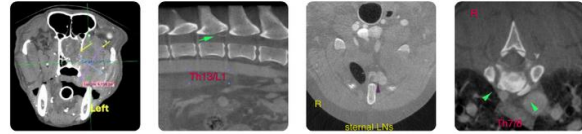
INVOICE

74171

DATE

3-12-26





Diagnostic Imaging

Veterinary CT, Ultrasound & Telemetry Services
veterinarian referral only

PATIENT

Ella Campeas

SPECIES

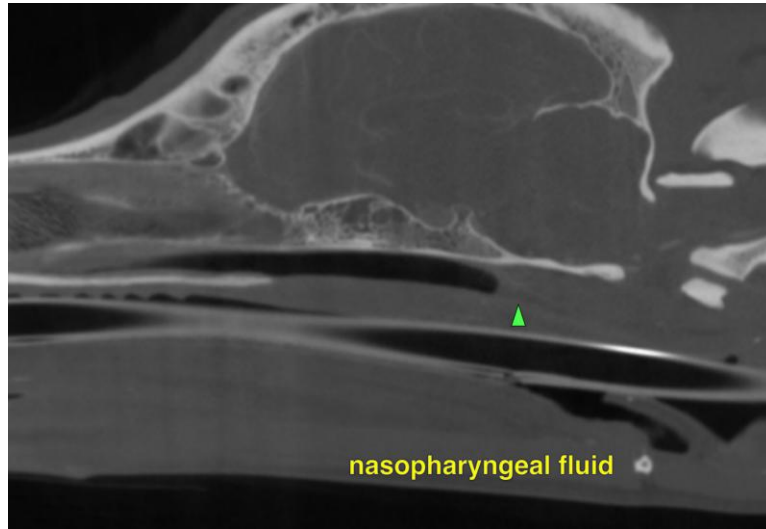
Canine

BREED

Terrier Mix

SEX

Female Spayed



AGE

5Y

The information and recommendations provided are based on the images presented by the referring veterinarian. No evaluation can be communicated regarding pathology that was not visible in the image/video clips provided.

INTERPRETED BY

Nele Eley (Ondreka),
DVM Dr. med. vet.,
DipECVDI

Thank you for this referral. If the clinical or image interpretation does not parallel your findings or if I can be of any further assistance please contact me.

Nele Eley (Ondreka), DVM, Dr. med. vet., DipECVDI
European Specialist in Veterinary Diagnostic Imaging, Cert. Radiology,
Senior lecturer University of Giessen/Germany, Veterinary Faculty, Department of Radiology.
info@sonopath.com

HOSPITAL NAME

Rockaway Animal
Hospital

REFERRING VET

Dr. Salazar

INVOICE

74171

DATE

3-12-26