



PATIENT

Misty Needle

SPECIES

Canine

BREED

Pittie

SEX

FS

AGE

6Y

WEIGHT

65lbs

INTERPRETED BY

Nele Eley (Ondreka),
DVM Dr. med. vet.,
DipECVDF

IMAGING PERFORMED BY

Kathleen Byrnes

HOSPITAL NAME

Byrnes Veterinary
Relief Services PC

REFERRING VET

Dr. Byrnes

INVOICE

73985

DATE

3-1-26

PRESENTING CLINICAL SIGNS

- P presented for exam due to 1 week history of lethargy, shaking, laying around not wanting to get up, yelped when putting collar on. mild lameness in L hind, L patella luxation.
- P had similar symptoms last year, mild lameness in R hind, referred to ortho, ACL 10-30% torn, luxating patella- TPLO and Patella surgery performed- recovered uneventfully, back to full activity
- P is VERY Sensitive

ULTRASONOGRAPHIC FINDINGS

Left Stifle

Moderate anechoic effusion and synovial proliferation are noted in the supra- and infra-patellar recesses of the left stifle joint. The medial collateral ligament presents mild thickening. Significant fiber disruption with anechoic halo consistent with effusion surrounding the ligament is seen at the cranial cruciate ligament. The lateral and medial menisci appear normal in position, morphology, and echogenicity. Mild osteophytosis is noted.

ULTRASONOGRAPHIC DIAGNOSIS

- Moderate left stifle effusion and synovitis.
- Early degenerative changes
- Partial to near complete rupture of the left cranial cruciate ligament.
- Menisci remain intact.

INTERPRETATION OF FINDINGS & FURTHER RECOMMENDATIONS

The ultrasonographic findings are consistent with cranial cruciate ligament pathology and suggests advanced partial to near complete rupture of the cranial cruciate ligament. Evidence of concomitant meniscal injury is not seen at this time. Mild to moderate osteoarthritic changes are present. Orthopedic consultation for surgical treatment such as TPLO, TTA, or other surgeon's preference is recommended.



PATIENT

Misty Needle

SPECIES

Canine

BREED

Pittie

SEX

FS

AGE

6Y

WEIGHT

65lbs

INTERPRETED BY

Nele Eley (Ondreka),
DVM Dr. med. vet.,
DipECVDI

IMAGING PERFORMED BY

Kathleen Byrnes

HOSPITAL NAME

Byrnes Veterinary
Relief Services PC

REFERRING VET

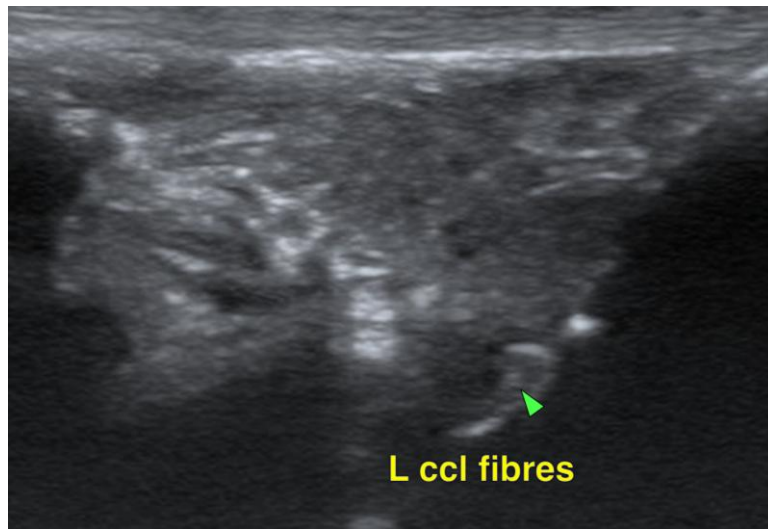
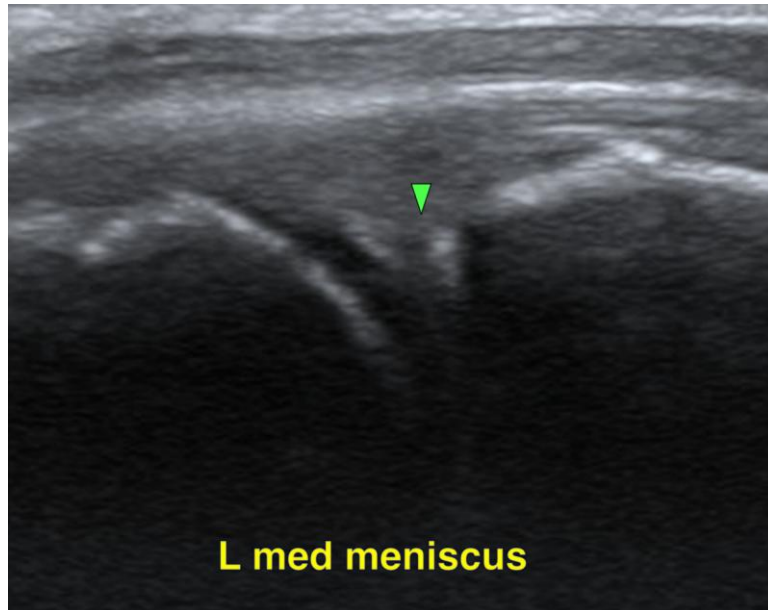
Dr. Byrnes

INVOICE

73985

DATE

3-1-26



The information and recommendations provided are based on the images presented by the referring veterinarian. No evaluation can be communicated regarding pathology that was not visible in the image/video clips provided.

Thank you for this referral. If the clinical or image interpretation does not parallel your findings or if I can be of any further assistance please contact me.

Nele Eley (Ondreka), DVM, Dr. med. vet., DipECVDI
European Specialist in Veterinary Diagnostic Imaging, Cert. Radiology,
Senior lecturer University of Giessen/Germany, Veterinary Faculty, Department of Radiology.
info@sonopath.com