

**PATIENT**

Slash Zhang

PRESENTING CLINICAL SIGNS

Slash had cat toy in mouth when the cat tree fell on top of him
Abnormal PE/Chem/CBC/UA Results: Pain to touch , (crooked mandibulae vs broken))
Swelling of right TMJ , penetrating wound just in front of right upper premolar High ALT
over1000 . mild inc of phosphorus /bilirubin

SPECIES

Feline

RADIOGRAPHIC STUDY OF THE HEAD

1 lateral, 2 lateral oblique, and 1 dorsoventral view of the head available for review.

BREED

DSH

RADIOGRAPHIC FINDINGS

The mandibular condyles and maxillary fovea do not appear to be in articulation on both sides. No overt fracture can be identified.

SEX

Female

Maxillomandibular shift and malocclusion with rightward shift of the maxilla appear to be present.

No evidence of a mandibular body fracture is seen.

AGE

12 Months

The tympanic bullae present within normal limits.

One of the upper canine teeth presents a complicated crown fracture.

INTERPRETED BY

Nele Eley, DVM
Dr. med. Vet. DipECVDF

No overt maxillary or maxillofacial fractures are seen.

RADIOGRAPHIC DIAGNOSIS

- Suspect bilateral temporomandibular joint luxation or subluxation.
- Maxillomandibular malocclusion.
- Complicated crown fracture of one maxillary canine tooth.

HOSPITAL NAME

St. Catherine's Animal
Hospital

INTERPRETATION OF THE FINDINGS & FURTHER RECOMMENDATIONS

The radiographic findings suggest bilateral temporomandibular joint luxation. Luxation fracture cannot be ruled out entirely. Consider sedated orthogonal views with bilateral lateral oblique projections of the temporomandibular joints, which can be achieved in a feline patient by a slight tilt of the nose upwards and downwards, respectively, in a right lateral position, if CT is not an option in this patient.

REFERRING VET

Dr. Mena

INVOICE

50618

DATE

3-1-22



PATIENT

Slash Zhang

SPECIES

Feline

BREED

DSH

SEX

Female

AGE

12 Months

INTERPRETED BY

Nele Eley, DVM
Dr. med. Vet. DipECVDI

HOSPITAL NAME

St. Catherine's Animal
Hospital

REFERRING VET

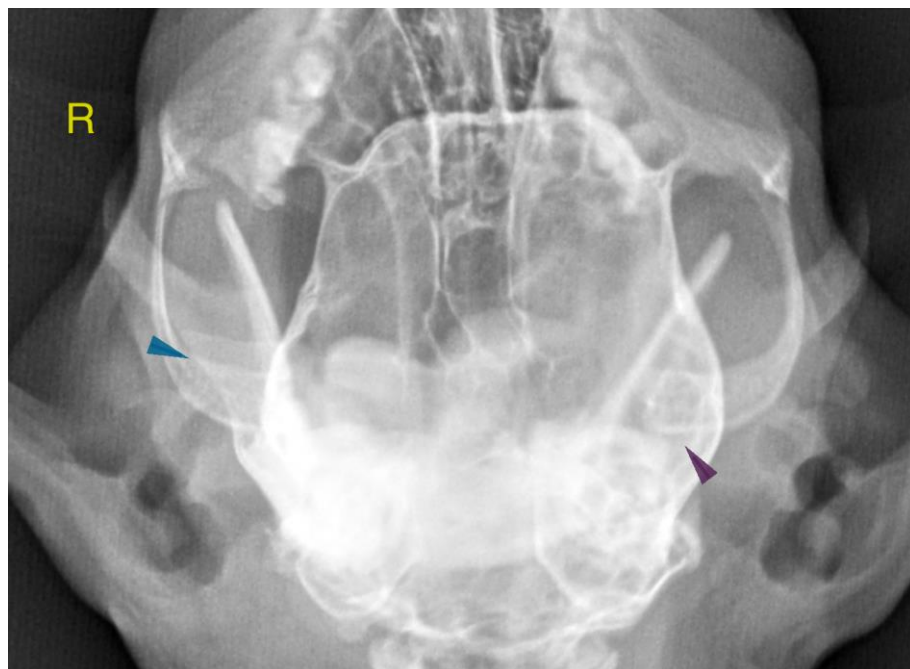
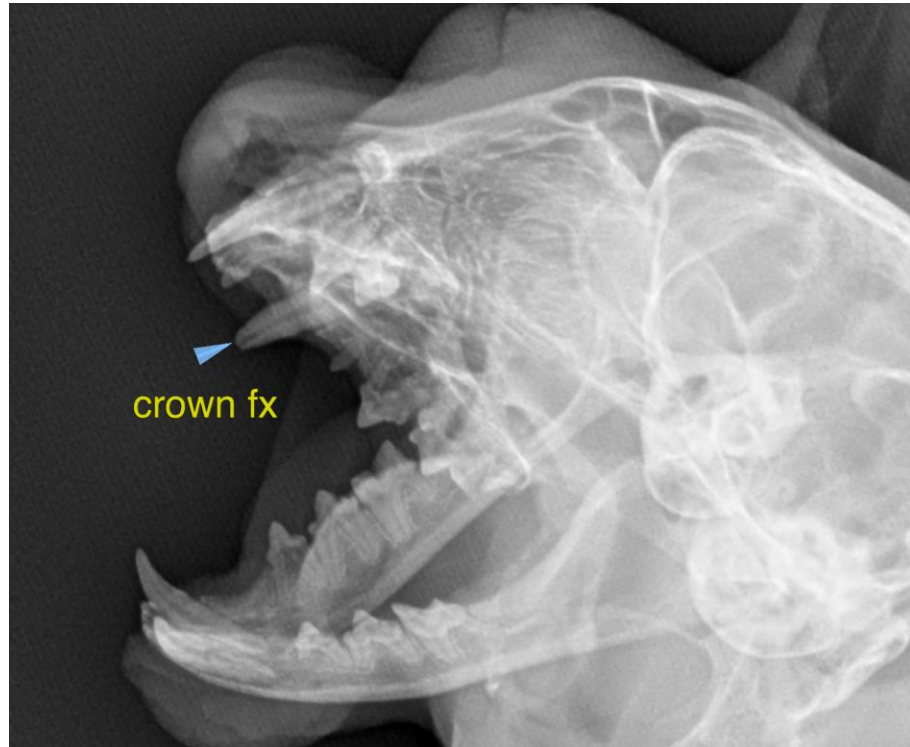
Dr. Mena

INVOICE

50618

DATE

3-1-22





PATIENT

Slash Zhang

The information and recommendations provided are based on the images presented by the referring veterinarian/sonographer. No evaluation can be communicated regarding pathology that was not visible in the image/video clips provided.

Thank you for this referral. If the clinical or image interpretation does not parallel your findings or if I can be of any further assistance please contact me.

SPECIES

Feline

Nele Eley, DVM, Dr. med. vet., DipECVDI
European Specialist in Veterinary Diagnostic Imaging, Cert. Radiology,
Senior lecturer University of Giessen, Germany, Veterinary Faculty, Department of Radiology
Nele.Eley@sonopath.com

BREED

DSH

SEX

Female

AGE

12 Months

INTERPRETED BY

Nele Eley, DVM
Dr. med. Vet. DipECVDI

HOSPITAL NAME

St. Catherine's Animal
Hospital

REFERRING VET

Dr. Mena

INVOICE

50618

DATE

3-1-22