



**PATIENT**

Brutus Sanchez

**PRESENTING CLINICAL SIGNS**

P is here for acting weird back legs swollen abdomen swollen eating ok, drinking a lot not urinating that often but is urinating ok  
Abnormal PE/Chem/CBC/UA Results: 2 view rads with consult cbc/chem

**SPECIES**

Canine

**RADIOGRAPHIC STUDY OF THE THORAX & ABDOMEN**

Right lateral and ventrodorsal views of the thorax and abdomen totaling 4 images available for review.

**BREED**

Chihuahua

**RADIOGRAPHIC FINDINGS**

**Abdomen**

The abdominal cavity is voluminous.

**SEX**

The ventral abdominal wall is pendulous. The abdominal serosal detail is severely reduced.

MN

The liver appears to be enlarged.

**AGE**

13 Years

No other overt mass effect or organomegaly is seen radiographically.

**Thorax**

**INTERPRETED BY**

Nele Eley, DVM  
Dr. med. Vet. DipECVDI

The thoracic volume is small.

Moderate left sided cardiomegaly with a vertebral heart score of 12.5 and marked left atrial tenting is seen. There also appears to be left auricular enlargement. At this time, there is no evidence of cardiogenic pulmonary edema. Mild rounding of the right ventricle with increased sternal contact and mild broadening of the caudal vena cava is seen as well.

**HOSPITAL NAME**

Animal Paradise  
Hospital

Course and width of the trachea area considered within normal limits.

**RADIOGRAPHIC DIAGNOSIS**

**REFERRING VET**

Dr. Kristen Hellwarth

- Severe abdominal effusion.
- Hepatomegaly.
- Moderate to severe left sided cardiomegaly with left atrial enlargement.
- No radiographic evidence of cardiogenic pulmonary edema.
- Potential for concurrent right sided cardiomegaly.

**INVOICE**

50631

**INTERPRETATION OF THE FINDINGS & FURTHER RECOMMENDATIONS**

A large amount of peritoneal fluid appears to be present. No overt abdominal organomegaly is seen. However, the assessment is limited owing to the reduced serosal detail.

**DATE**

3-1-22

The liver appears to be enlarged. Differential diagnosis includes metabolic/endocrine, inflammatory/infectious, and neoplastic pathology as well as congestion owing to right sided congestive heart failure. Consider further definition by means of full abdominal ultrasound.



**PATIENT**

Brutus Sanchez

Left sided cardiomegaly appears to be prioritized and mitral valve regurgitation, owing to myxomatous degeneration, is considered very likely. Concurrent tricuspid valve regurgitation cannot be ruled out. Consider a cardiac echo for further definition. Aspiration and analysis of the abdominal fluid should be considered in the further workup as well.

**SPECIES**

Canine

**BREED**

Chihuahua

**SEX**

MN

**AGE**

13 Years

**INTERPRETED BY**

Nele Eley, DVM  
Dr. med. Vet. DipECVDI

**HOSPITAL NAME**

Animal Paradise  
Hospital

**REFERRING VET**

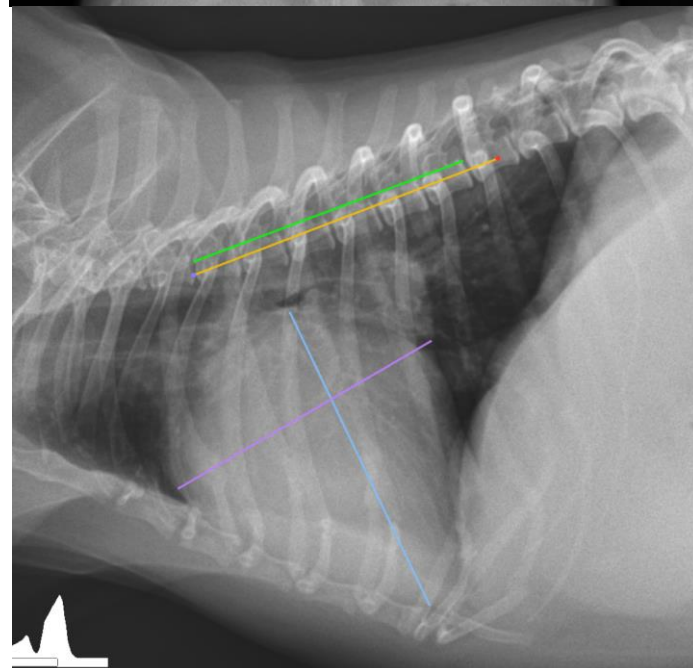
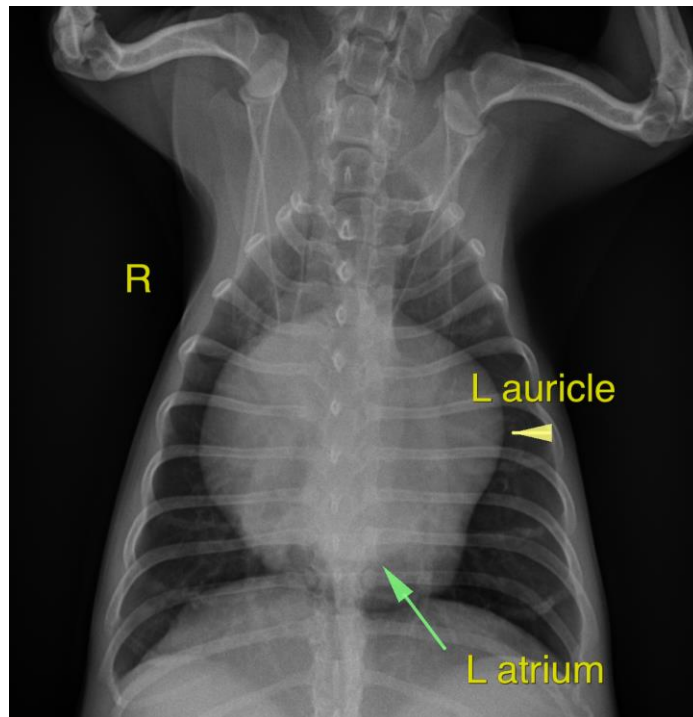
Dr. Kristen Hellwarth

**INVOICE**

50631

**DATE**

3-1-22





### PATIENT

Brutus Sanchez

The information and recommendations provided are based on the images presented by the referring veterinarian/sonographer. No evaluation can be communicated regarding pathology that was not visible in the image/video clips provided.

### SPECIES

Canine

Thank you for this referral. If the clinical or image interpretation does not parallel your findings or if I can be of any further assistance please contact me.

### BREED

Chihuahua

**Nele Eley**, DVM, Dr. med. vet., DipECVDI  
European Specialist in Veterinary Diagnostic Imaging, Cert. Radiology,  
Senior lecturer University of Giessen, Germany, Veterinary Faculty, Department of Radiology  
Nele.Eley@sonopath.com

### SEX

MN

### AGE

13 Years

### INTERPRETED BY

Nele Eley, DVM  
Dr. med. Vet. DipECVDI

### HOSPITAL NAME

Animal Paradise  
Hospital

### REFERRING VET

Dr. Kristen Hellwarth

### INVOICE

50631

### DATE

3-1-22