



PATIENT

Karma Jaensch

SPECIES

Canine

BREED

Greyhound

SEX

Male

AGE

2Y

WEIGHT

32kg

INTERPRETED BY

Nele Eley (Ondreka),
DVM Dr. med. vet.,
DipECVDI

IMAGING PERFORMED BY

J Allan

HOSPITAL NAME

Adelaide Plains
Veterinary Surgery

REFERRING VET

Dr E Klopp

INVOICE

73676

DATE

2-9-26

PRESENTING CLINICAL SIGNS

- Track injury 4/2
- Xrays taken
- Findings- there looks to be multiple fractures and a large fragment from the distal caudal aspect.
- CT on Tuesday for further evaluation

COMPUTED TOMOGRAPHIC STUDY OF THE CARPI

Plain study in soft tissue and bone windows is available for review.

COMPUTED TOMOGRAPHIC FINDINGS

Right Carpus

The CT study reveals a severely comminuted acute fracture of the right accessory carpal bone. The main fracture line is sagittal oblique extending throughout the length of the accessory carpal bone from palmar to dorsal into the dorsal articular surface at the articulation with the 4th carpal bone. Multiple small fragments are seen predominantly at the base of the accessory carpal bone with additional fragments at the distal tip of the accessory carpal bone. Mild proximal angulation of the accessory carpal bone is noted. Extensive periarticular soft tissue swelling is seen surrounding the accessory carpal bone. The mild proximal angulation of the accessory carpal bone raises concern for possible involvement of the accessory metacarpal ligament distal to the accessory carpal bone. Involvement of the flexor carpi ulnaris tendon also cannot be excluded.

Left Carpus

No acute traumatic abnormalities identified.

Incidental/chronic findings:

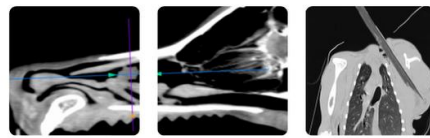
Mild bilaterally symmetric osteophyte formation along the dorsal aspect of the radiocarpal bone bilaterally.

COMPUTED TOMOGRAPHIC DIAGNOSIS

- Severely comminuted acute fracture of the right accessory carpal bone with intraarticular extension.
- Extensive surrounding soft tissue injury with suspected associated ligamentous or tendinous involvement.
- Mild chronic bilateral carpal osteoarthritis – likely incidental.

INTERPRETATION OF FINDINGS & FURTHER RECOMMENDATIONS

The accessory carpal bone is a critical lever arm for the flexor carpi ulnaris muscle and stabilizing ligaments. Fractures of this severity, especially with comminution and articular involvement, can be associated with carpal instability. Clinical correlation is required. The degree of fragmentation and suspected soft tissue injury render conservative management less predictable, particularly in a young athletic greyhound with high functional demands. Orthopedic consultation is strongly recommended if not performed already. Surgical management could be considered given the comminution,



PATIENT

Karma Jaensch

SPECIES

Canine

BREED

Greyhound

SEX

Male

AGE

2Y

WEIGHT

32kg

INTERPRETED BY

Nele Eley (Ondreka),
DVM Dr. med. vet.,
DipECVDI

IMAGING PERFORMED BY

J Allan

HOSPITAL NAME

Adelaide Plains
Veterinary Surgery

REFERRING VET

Dr E Klopp

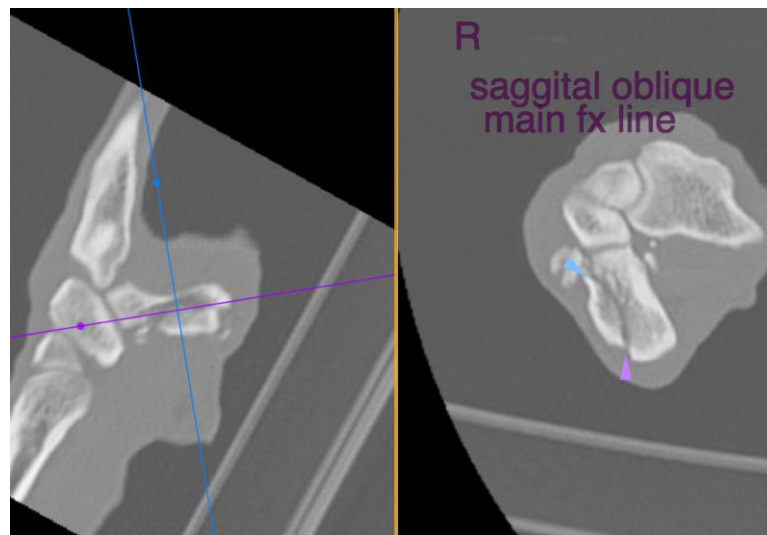
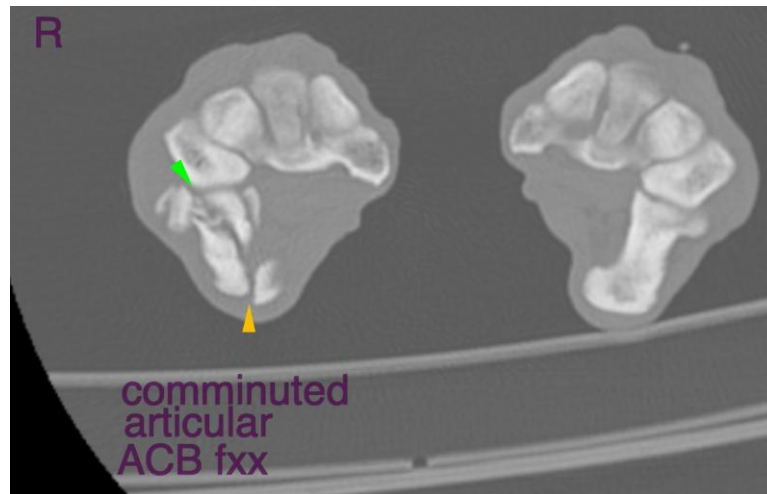
INVOICE

73676

DATE

2-9-26

intraarticular involvement, and suspected soft tissue damage. Strict immobilization and prolonged rest would be required for conservative management. Overall prognosis is guarded to fair depending on the extent of associated soft tissue injury and response to treatment.



The information and recommendations provided are based on the images presented by the referring veterinarian. No evaluation can be communicated regarding pathology that was not visible in the image/video clips provided.

Thank you for this referral. If the clinical or image interpretation does not parallel your findings or if I can be of any further assistance please contact me.

Nele Eley (Ondreka), DVM, Dr. med. vet., DipECVDI
European Specialist in Veterinary Diagnostic Imaging, Cert. Radiology,
Senior lecturer University of Giessen/Germany, Veterinary Faculty, Department of Radiology.
info@sonopath.com