

**PATIENT**

Chuchi Rescue Dogs
Rock NYC

PRESENTING CLINICAL SIGNS

Dec 2022 hit by car

SPECIES

Canine

RADIOGRAPHIC STUDY OF THE HEAD & NECK

Lateral, oblique, dorsoventral, dorsoventral open mouth views of the head and neck totaling 4 images available for review.

BREED

Chihuahua

The patient has a history of road traffic accident in December 2022.

SEX

MI

A complete transverse fracture of the right caudal mandibular body is seen involving the dental alveolus, roots, and crowns of the triadan 409. The distal crown and root appear to be separated from the mesial roots and crowns. Multiple tooth fragments are present. There is a large amount of heterogeneous callous formation bridging the diastema of the fracture. A radiolucent halo is present circumferential to all roots of the triadan 409 and the dental fragments which presumably stem from a comminuted fractured triadan 410 and/or 411 circumferentially. Mild maxillomandibular malocclusion with leftward shift of the mandibles is seen.

AGE

10 Months

The temporomandibular joints appear to be in situ.

The tympanic bullae are aerated and appear to be intact.

No evidence of atlantoaxial subluxation or injury is seen.

INTERPRETED BY

Nele Eley, DVM
Dr. med. Vet. DipECVDI

Number, alignment, and general anatomy of the cervical vertebrae present within age related normal limits.

RADIOGRAPHIC DIAGNOSIS

- Malunion fracture of the caudal right mandibular body level with the triadans 409 & 410 with associated dental fractures and maxillomandibular malocclusion.

HOSPITAL NAME

Animal Surgical
Center

INTERPRETATION OF THE FINDINGS & FURTHER RECOMMENDATIONS**REFERRING VET**

East Village AH

The radiographic study supports the presence of a malunion fracture of the right caudal mandible with dental involvement. The fracture is in the late repair phase. The fracture segments appear to be mostly unified however lack of osseous healing is seen circumferential to the fractured tooth roots of the triadans 409, 410, and presumably also 411.

INVOICE

56712

DATE

2-9-23



PATIENT

Chuchi Rescue Dogs
Rock NYC

SPECIES

Canine

BREED

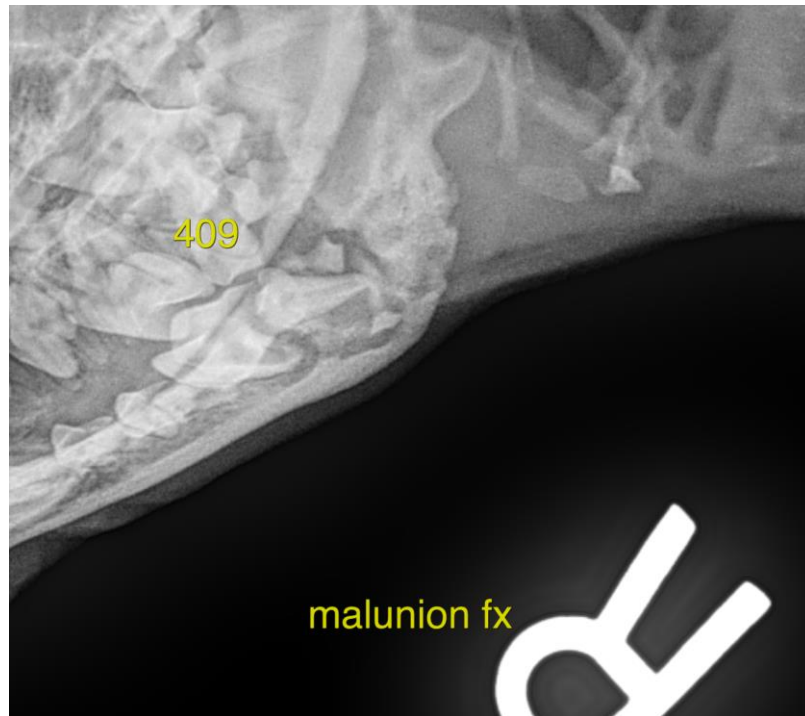
Chihuahua

SEX

MI

AGE

10 Months



INTERPRETED BY

Nele Eley, DVM
Dr. med. Vet. DipECVDI

The information and recommendations provided are based on the images presented by the referring veterinarian/sonographer. No evaluation can be communicated regarding pathology that was not visible in the image/video clips provided.

Thank you for this referral. If the clinical or image interpretation does not parallel your findings or if I can be of any further assistance please contact me.

HOSPITAL NAME

Animal Surgical
Center

Nele Eley, DVM, Dr. med. vet., DipECVDI
European Specialist in Veterinary Diagnostic Imaging, Cert. Radiology,
Senior lecturer University of Giessen, Germany, Veterinary Faculty, Department of Radiology
Nele.Eley@sonopath.com

REFERRING VET

East Village AH

INVOICE

56712

DATE

2-9-23