



**PATIENT**

Whiskey Frye

**PRESENTING CLINICAL SIGNS**

discomfort on the base of the tail and trying to bite a lot the base of the tail. During physical exam no pain but on x ray there is radiopaque area under the tail beside the rectum.

**SPECIES**

Feline

**RADIOGRAPHIC STUDY OF THE TAIL BASE**

Lateral and dorsoventral views totaling 5 images available for review.

**BREED**

Domestic Shorthair  
Mix

**RADIOGRAPHIC FINDINGS**

The patient has a sacrococcygeal transitional vertebra which is an incidental finding.

Circumferential and symmetric thickening of the anal sphincter and/or caudal rectal wall appears to be present. The soft tissue thickening appears to be well delineated and symmetrically in a midline position. No evidence of coprostitis is seen.

**SEX**

Neutered Male

The surrounding osseous structures are distant from the soft tissue thickening and present no deviation from their expected anatomy.

**RADIOGRAPHIC DIAGNOSIS**

- Caudal rectal / perirectal soft tissue swelling of undetermined origin.

**AGE**

8 Years

**INTERPRETATION OF THE FINDINGS & FURTHER RECOMMENDATIONS**

The radiographic study reveals well delineated soft tissue swelling level with the caudal rectal wall and anal sphincter. Regional inflammation and a diffuse wall infiltrate appear to be the most likely differential diagnoses. With the obvious limitations of radiographic assessment of the soft tissues, consider further definition by means of palpation, ultrasound, and/or computed tomography as well as fine needle aspiration of the soft tissue swelling.

**INTERPRETED BY**

Nele Eley, DVM  
Dr. med. Vet. DipECVDI

**HOSPITAL NAME**

Truscott Animal  
Hospital

**REFERRING VET**

Medhat Meawad

**INVOICE**

50215

**DATE**

2-9-22



**PATIENT**

Whiskey Frye

**SPECIES**

Feline

**BREED**

Domestic Shorthair  
Mix

**SEX**

Neutered Male

**AGE**

8 Years

**INTERPRETED BY**

Nele Eley, DVM  
Dr. med. Vet. DipECVDI

**HOSPITAL NAME**

Truscott Animal  
Hospital

**REFERRING VET**

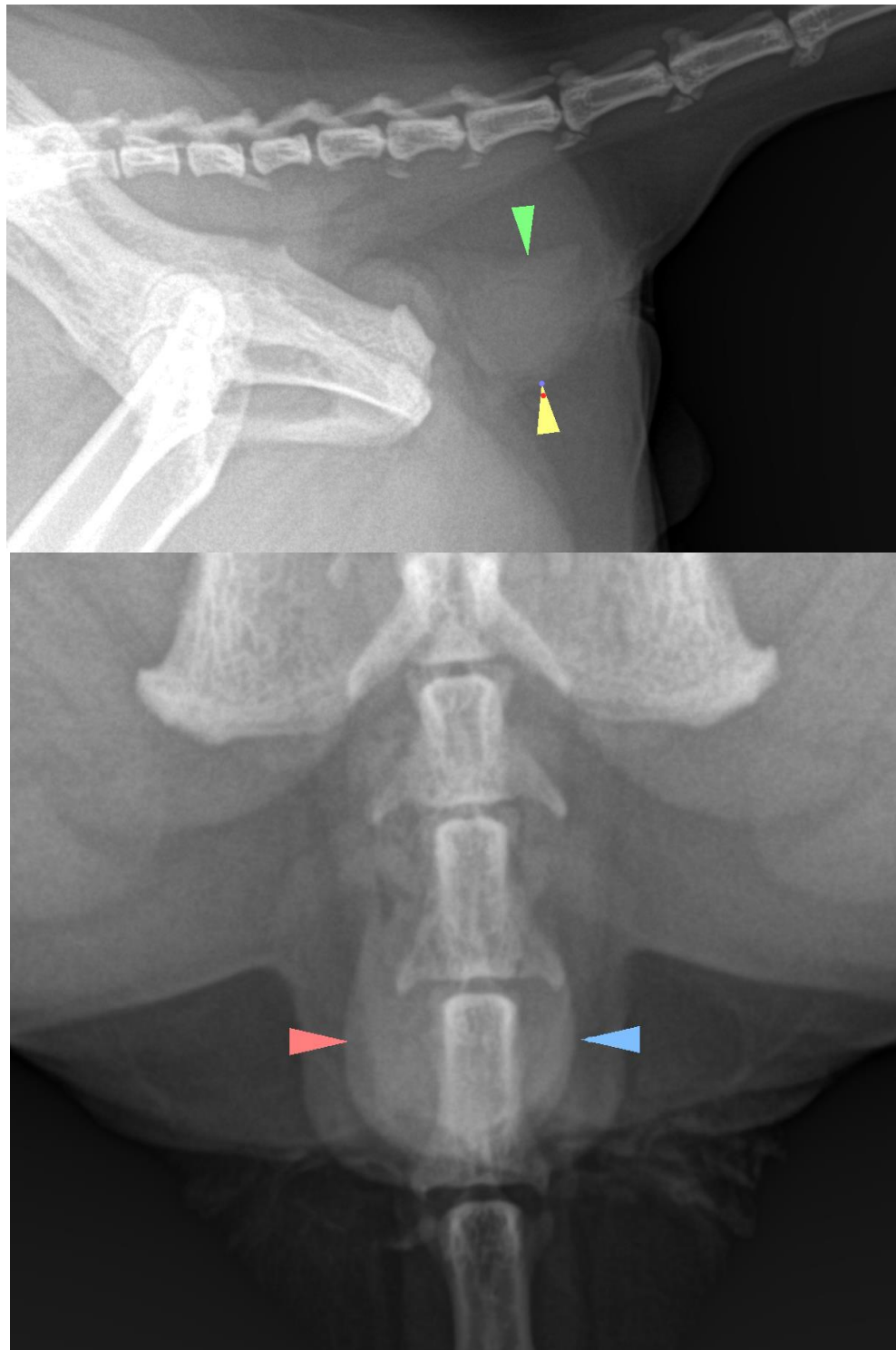
Medhat Meawad

**INVOICE**

50215

**DATE**

2-9-22





**PATIENT**

Whiskey Frye

The information and recommendations provided are based on the images presented by the referring veterinarian/sonographer. No evaluation can be communicated regarding pathology that was not visible in the image/video clips provided.

Thank you for this referral. If the clinical or image interpretation does not parallel your findings or if I can be of any further assistance please contact me.

**SPECIES**

Feline

**Nele Eley**, DVM, Dr. med. vet., DipECVDI  
European Specialist in Veterinary Diagnostic Imaging, Cert. Radiology,  
Senior lecturer University of Giessen, Germany, Veterinary Faculty, Department of Radiology  
Nele.Eley@sonopath.com

**BREED**

Domestic Shorthair  
Mix

**SEX**

Neutered Male

**AGE**

8 Years

**INTERPRETED BY**

Nele Eley, DVM  
Dr. med. Vet. DipECVDI

**HOSPITAL NAME**

Truscott Animal  
Hospital

**REFERRING VET**

Medhat Meawad

**INVOICE**

50215

**DATE**

2-9-22