



PATIENT

Marley Gabriele

PRESENTING CLINICAL SIGNS

Vomiting and diarrhea x 4 days. History of foreign body ingestion.
Abnormal PE/Chem/CBC/UA Results: BW pending

SPECIES

Canine

RADIOGRAPHIC STUDY OF THE ABDOMEN

Right/left lateral and ventrodorsal views totaling 3 images available for review.

BREED

Shorkie

RADIOGRAPHIC FINDINGS

The surrounding bony structures are within normal limits.

SEX

MN

No abnormalities of the extraabdominal soft tissues are noted. The abdominal wall is smooth and thin.

The serosal detail is maintained throughout the peritoneal and retroperitoneal space.

AGE

1.25 Years

The liver is appropriate in position, size and presents uniform opacity.

The splenic head is in the anticipated position and within normal limits for size and opacity. The splenic body and tail are considered normal for position, size, shape and opacity.

Both kidneys are seen and present with normal size, shape, delineation and opacity. The urinary bladder is in its anticipated position. No radiopaque calculi are noted throughout the upper and lower urinary tract.

INTERPRETED BY

Nele Eley, DVM
Dr. med. Vet. DipECVDI

The stomach contains a moderate amount of gas.

No overt evidence of small intestinal dilation, plication, or radiopaque foreign material is seen.

HOSPITAL NAME

Four Corners
Veterinary Practice

The gas contained within the bowel in the right cranial abdomen is most likely situated within the cecum and ascending colon. The descending colon appears to be empty.

RADIOGRAPHIC DIAGNOSIS

- Gastrointestinal maldigestion pattern.

REFERRING VET

Gregory Roccaro

INTERPRETATION OF THE FINDINGS & FURTHER RECOMMENDATIONS

The radiographic study reveals no overt evidence of mechanical ileus. Functional ileus is considered most likely based on the radiographic findings and patient history. Subileus cannot be ruled out entirely and further definition by means of ultrasound should be considered in case of persisting or deteriorating clinical signs.

INVOICE

50212

DATE

2-9-22



PATIENT

Marley Gabriele

SPECIES

Canine

BREED

Shorkie

SEX

MN

AGE

1.25 Years

INTERPRETED BY

Nele Eley, DVM
Dr. med. Vet. DipECVDI

HOSPITAL NAME

Four Corners
Veterinary Practice

REFERRING VET

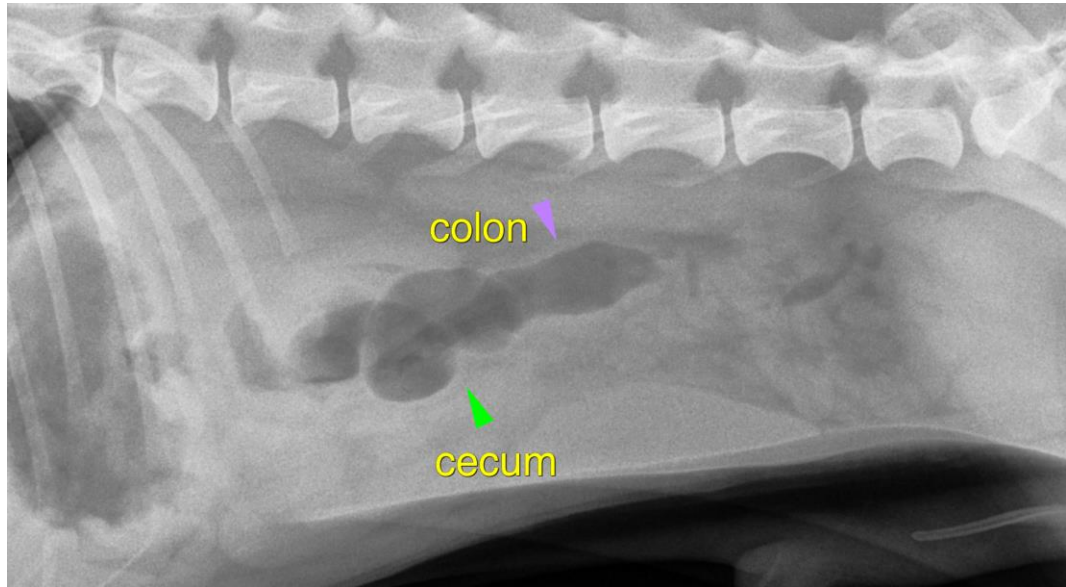
Gregory Roccaro

INVOICE

50212

DATE

2-9-22



The information and recommendations provided are based on the images presented by the referring veterinarian/sonographer. No evaluation can be communicated regarding pathology that was not visible in the image/video clips provided.

Thank you for this referral. If the clinical or image interpretation does not parallel your findings or if I can be of any further assistance please contact me.

Nele Eley, DVM, Dr. med. vet., DipECVDI
European Specialist in Veterinary Diagnostic Imaging, Cert. Radiology,
Senior lecturer University of Giessen, Germany, Veterinary Faculty, Department of Radiology
Nele.Eley@sonopath.com