

**PATIENT**

Harley Russell

**PRESENTING CLINICAL SIGNS**

Chronic allergic skin disease Ruptured Right Cruciate - TTA correctio surgery April 4 2021 \*\* doing well on this knee. Started limping and favoring left knee Dec 2021  
Abnormal PE/Chem/CBC/UA Results: Medial buttress, Cranial drawer and CTT in the left knee

**SPECIES**

Canine

**ULTRASONOGRAPHIC FINDINGS****Left Stifle**

A large amount of anechoic effusion is present within the supra- and infra- patellar recesses of the left stifle joint. There is extensive synovial swelling.

**BREED**

Pitbull Mix

The cranial cruciate ligament presents as a stump of echogenic fibers at the intercondylar eminence of the tibia surrounded by a halo of anechoic effusion. Infrapatellar fat pad heterogeneity is seen.

**SEX**

MN

The lateral and medial menisci are in situ. No evidence of prolapse or meniscal injury is seen ultrasonographically.

**AGE**

2 Years, 5 Months

**ULTRASONOGRAPHIC DIAGNOSIS**

- Moderate to severe left stifle osteoarthritis with full rupture of the cranial cruciate ligament.

**INTERPRETED BY**

Nele Eley, DVM  
Dr. med. Vet. DipECVDI

**INTERPRETATION OF THE FINDINGS & FURTHER RECOMMENDATIONS**

The ultrasonographic study reveals full rupture of the left cranial cruciate ligament with extensive osteoarthritis changes within all compartments of the stifle joint. No evidence of meniscal injury can be identified ultrasonographically in the available images.

**HOSPITAL NAME**

Westview Veterinary  
Hospital

**REFERRING VET**

Dr. Brian Barnes

**INVOICE**

50198

**DATE**

2-9-22



**PATIENT**

Harley Russell

**SPECIES**

Canine

**BREED**

Pitbull Mix

**SEX**

MN

**AGE**

2 Years, 5 Months

**INTERPRETED BY**

Nele Eley, DVM  
Dr. med. Vet. DipECVDI

**HOSPITAL NAME**

Westview Veterinary  
Hospital

**REFERRING VET**

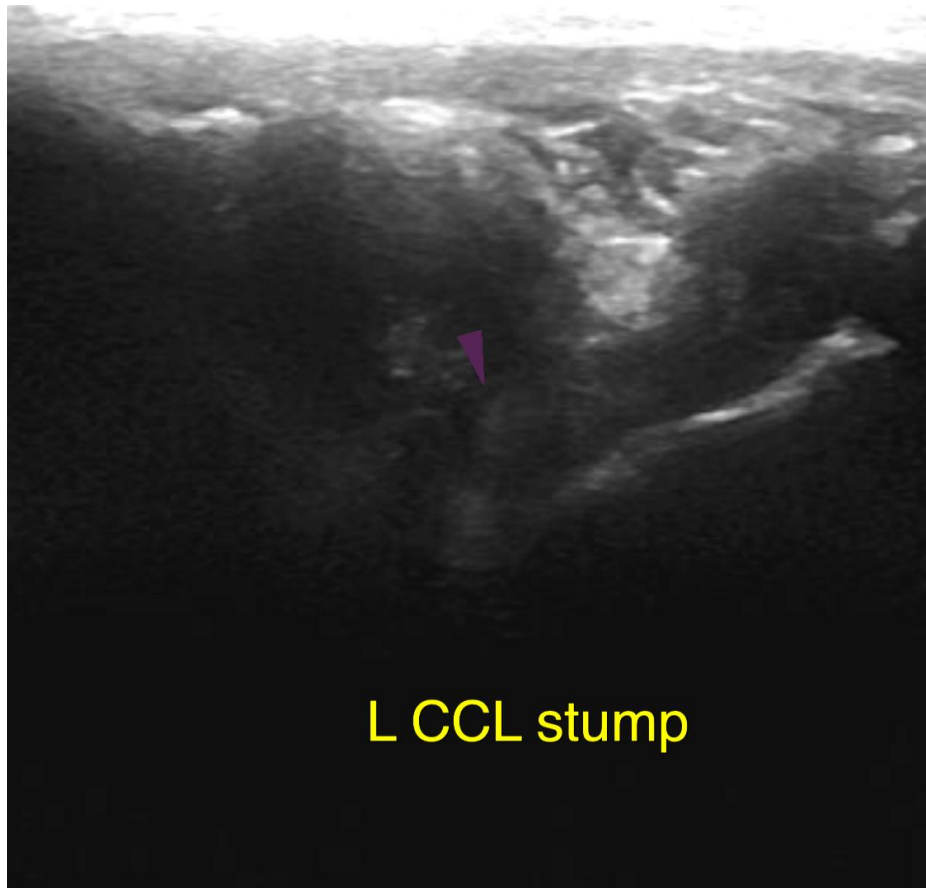
Dr. Brian Barnes

**INVOICE**

50198

**DATE**

2-9-22



The information and recommendations provided are based on the images presented by the referring veterinarian/sonographer. No evaluation can be communicated regarding pathology that was not visible in the image/video clips provided.

Thank you for this referral. If the clinical or image interpretation does not parallel your findings or if I can be of any further assistance please contact me.

**Nele Eley**, DVM, Dr. med. vet., DipECVDI  
European Specialist in Veterinary Diagnostic Imaging, Cert. Radiology,  
Senior lecturer University of Giessen, Germany, Veterinary Faculty, Department of Radiology  
Nele.Eley@sonopath.com