



PATIENT

Barbie Benitez

PRESENTING CLINICAL SIGNS

Pet is have a little bump in the right side and sometimes has blood in the urine.

SPECIES

Canine

RADIOGRAPHIC STUDY OF THE THORAX & ABDOMEN

Right lateral and ventrodorsal views of the abdomen and thorax totaling 4 images available for review.

BREED

Shih Tzu

RADIOGRAPHIC FINDINGS

Abdomen

A 1.5 x 2.0 cm sized soft tissue opaque nodule is seen in the inguinal area.

SEX

Spayed

The urinary bladder is mildly distended. No evidence of abnormal opacities is seen. There is no evidence of sublumbar lymphadenomegaly.

The stomach is post-prandial.

AGE

11

The small intestinal loops are mildly turgid in appearance yet of normal diameter.

Medial patella luxation of the right stifle is seen.

Both coxofemoral joints present mild osteoarthritic changes.

INTERPRETED BY

Nele Eley, DVM
Dr. med. Vet. DipECVDI

Thorax

Both shoulder joints present moderate osteoarthritic changes.

Redundancy of the dorsal tracheal ligament of the caudal cervical trachea is noted.

HOSPITAL NAME

Animal Paradise
Hospital

There is no radiographic evidence of cardiovascular pathology.

The radiographic presentation of the lung and bronchial tree is considered within age related normal limits.

REFERRING VET

Dr. Elshafie

No evidence of abnormal mediastinal widening is seen.

RADIOGRAPHIC DIAGNOSIS

INVOICE

50214

- Subcutaneous inguinal soft tissue nodule.
- Normal radiographic presentation of the urinary bladder.
- Right medial patella luxation.
- Mild right stifle osteoarthritis.
- Mild bilateral coxofemoral joint osteoarthritis.
- Bilateral shoulder osteoarthritis.
- Redundancy of the dorsal tracheal ligament.

DATE

2-9-22



PATIENT

Barbie Benitez

INTERPRETATION OF THE FINDINGS & FURTHER RECOMMENDATIONS

There appears to be an inguinal soft tissue nodule. Consider mammary nodule, other neoplastic nodule, and less likely hematoma cyst, abscess, or granuloma. Consider fine needle aspiration for further definition depending on the clinical correlation.

SPECIES

Canine

The radiographic presentation of the urinary bladder was within normal limits. However, owing to the pertinent history, lower urinary tract infection, neoplastic, and other pathology of the lower urinary tract could be a potential which all require further definition by means of ultrasound.

BREED

Shih Tzu

There was no radiographic evidence of sublumbar lymphadenomegaly.

SEX

Spayed

The redundancy of the dorsal tracheal ligament may well be an incidental finding. Dynamic tracheal disease cannot be ruled out entirely. Clinical correlation warranted.

AGE

11

INTERPRETED BY

Nele Eley, DVM
Dr. med. Vet. DipECVDI

HOSPITAL NAME

Animal Paradise
Hospital

REFERRING VET

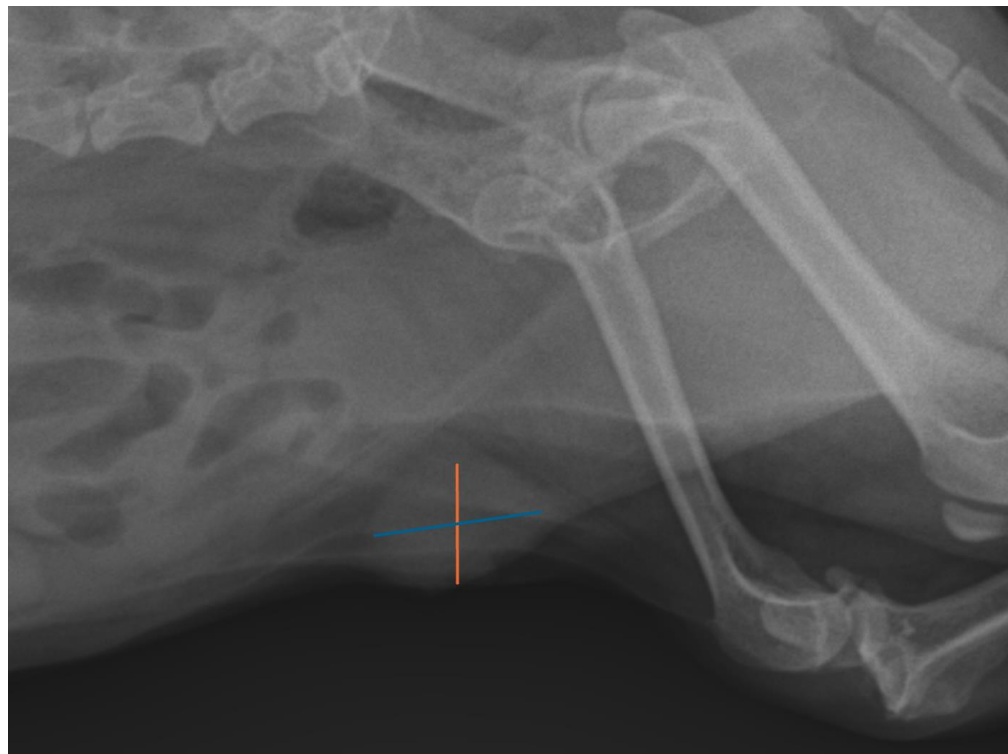
Dr. Elshafie

INVOICE

50214

DATE

2-9-22





PATIENT

Barbie Benitez

The information and recommendations provided are based on the images presented by the referring veterinarian/sonographer. No evaluation can be communicated regarding pathology that was not visible in the image/video clips provided.

Thank you for this referral. If the clinical or image interpretation does not parallel your findings or if I can be of any further assistance please contact me.

SPECIES

Canine

Nele Eley, DVM, Dr. med. vet., DipECVDI
European Specialist in Veterinary Diagnostic Imaging, Cert. Radiology,
Senior lecturer University of Giessen, Germany, Veterinary Faculty, Department of Radiology
Nele.Eley@sonopath.com

BREED

Shih Tzu

SEX

Spayed

AGE

11

INTERPRETED BY

Nele Eley, DVM
Dr. med. Vet. DipECVDI

HOSPITAL NAME

Animal Paradise
Hospital

REFERRING VET

Dr. Elshafie

INVOICE

50214

DATE

2-9-22